

### Shrinking Lung Syndrome – A rare cause of recurrent dyspnoea in SLE

Hazlyna Baharuddin<sup>1</sup>, Mohd Arif Mohd Zim<sup>1</sup>, Azmillah Rosman<sup>2</sup>, Mollyza Mohd Zain<sup>2</sup>

1 Faculty of Medicine, Universiti Teknologi MARA, Selangor, Malaysia

2 Rheumatology Unit, Hospital Selayang

#### Received

1<sup>st</sup> February 2016

#### Received in revised form

23<sup>rd</sup> January 2017

#### Accepted

4<sup>th</sup> March 2017

#### Corresponding author:

**Dr Hazlyna Baharuddin,**

Faculty of Medicine,

Selayang Campus,

Universiti Teknologi MARA (UiTM),

68100 Batu Caves,

Selangor, Malaysia.

Tel: +6012-6173021

Email:

hazlynabaharuddin@yahoo.com

#### ABSTRACT

Here we present a 24-year-old lady with systemic lupus erythematosus (SLE) whom we diagnosed with shrinking lung syndrome (SLS), a rare manifestation of SLE. The initial SLE manifestation was alopecia, thrombocytopenia, serositis and vasculitis. Anti-nuclear antibody (ANA), anti-double stranded DNA (dsDNA) antibody, anti-ribonucleic (RNP) and anti-Ro antibody were positive. A year after diagnosis, she started to develop intermittent dyspnea and was hospitalised on three occasions. Lung examinations revealed reduced breath sounds at both bases and dullness at the right base. Multiple chest radiographs showed bilateral raised hemi-diaphragms. Other investigations including CT pulmonary angiogram, high resolution CT of the thorax, ventilation-perfusion scan and echocardiogram were not significant. On the third hospital admission, we noticed bilateral small lung volumes in the previous high resolution CT scan. Inspiratory and expiratory chest radiographs were performed and showed minimal change in lung volumes and a diagnosis of shrinking lung syndrome (SLS) was made. Her SLE remained active with lupus nephritis despite multiple immunosuppression and she passed away two years later due to sepsis with multi-organ failure.

**KEYWORDS:** Lupus, small volumes, raised hemi-diaphragms, shrinking lung syndrome, nephritis.

#### INTRODUCTION

Shrinking lung syndrome (SLS) is a rare manifestation of SLE. It is reported to be the least common manifestation of pulmonary impairment in SLE and its pathogenesis is unclear. It is characterised by Hoffbrand as unexplained dyspnea, small lung volumes and restrictive lung physiology with or without diaphragmatic elevation in the absence of interstitial, alveolar or vascular pulmonary disease on chest imaging [1]. The prevalence of SLS varies according to different studies. The most recent review in 2016 reported only 1.1% cases of SLS (9 of 829 SLE) over 35 years from three rheumatology referral centres in Spain [2], while another study in Canada reported 10% SLS cases among 110 patients [3]. Here we present a young lady with SLE, whose recurrent dyspnoea was due to SLS.

#### CASE PRESENTATION

A 24-year old lady with systemic lupus erythematosus (SLE) was investigated for intermittent dyspnoea

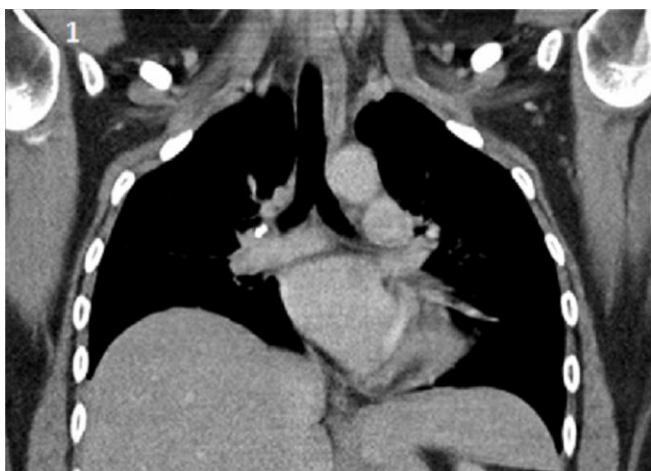which started a year after she was diagnosed with SLE. She was referred for further management of SLE in 2010. She presented two months earlier with alopecia, thrombocytopenia, serositis (pericardial and pleural effusion) and gangrenous toes secondary to vasculitis. Immunology tests revealed positive anti-nuclear antibody (ANA) with a titre of 1:160, anti-double stranded DNA (dsDNA) antibodies, anti-ribonucleic (RNP) antibodies and anti-Ro antibodies, as well as low complements. Antiphospholipid antibodies and other vasculitic screen were negative. We treated her with high dose steroid and she was discharged well on prednisolone and hydroxychloroquine.

She presented with dyspnoea a year after that and lung examination revealed reduced breath sounds at both bases and dullness to percussion at right base up to the midzone. Pleural tap was performed and the pleural fluid was exudative. She was treated for pneumonia and SLE flare with serositis. Apart from increment of steroid dose, azathioprine was started as steroid sparing agent. Two subsequent chest radiographs done in the same year after she was

discharged revealed reduced lung volumes bilaterally with raised hemi-diaphragms, which were thought to be due to poor inspiratory effort.

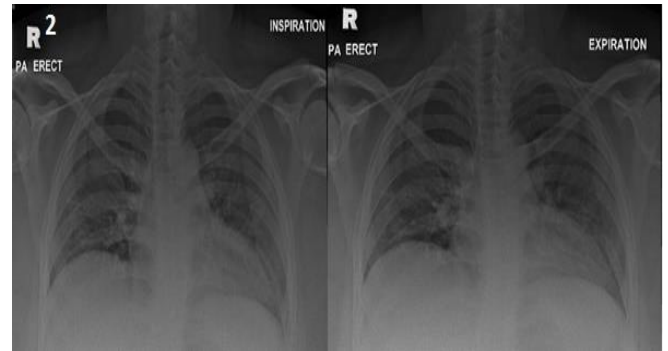
In 2012, she was admitted to nephrology ward for work-up of proteinuria. During this admission, she developed two episodes of dyspnea and she required non-invasive ventilation on one of these occasions. Lung examinations revealed persistent dullness at the right base and reduced breath sounds at both bases. Chest radiographs were essentially unchanged from previous images and CT pulmonary angiogram did not show evidence of pulmonary embolism. She received two courses of antibiotics and warfarin was started for the possibility of pulmonary embolism, while waiting for ventilation perfusion scan (VQ scan) as out-patient. She also received a course of methylprednisolone followed by mycophenolate mofetil when the renal biopsy confirmed lupus nephritis Class III and IV.

During a routine clinic for international normalised ratio (INR) review six months later, she was noted to be dyspnoeic and was readmitted to rheumatology ward for investigation. On examination, she was tachycardic with pulse rate of 118 beats per minute and tachypnoeic with respiratory rate of 28 breaths per minute. The oxygen saturation was 98% in room air. Her body mass index (BMI) was 37 kg/m<sup>2</sup> and she admitted to significant weight gain since a year ago. Lung examination revealed reduced breath sounds at the bases but no stony dullness to percussion. A repeat chest radiograph revealed reduced lung volumes bilaterally with elevated hemidiaphragms.



**Figure 1** Transverse section of CT scan. There is reduced lung volumes bilaterally

A VQ scan and high resolution CT (HRCT) scan done as out-patient earlier on, revealed a low probability of pulmonary embolism and presence of segmental atelectasis in the right upper lobe with no lung fibrosis, respectively. However, we noticed bilateral small lung fields in the HRCT, when we had another look at the HRCT (Fig 1). We performed inspiratory and expiratory chest radiographs, which revealed no changes in the lung volumes (Fig. 2).



**Figure 2** Inspiration and expiration chest x-ray. Small lung volumes is indicated by the level of hemidiaphragm which coincide with the second rib anteriorly. There is reduced chest expansion of the lungs indicated by minimal movement of the hemidiaphragms on inspiration and expiration.

Other investigations, included tuberculosis and septic work-up were negative and an echocardiogram revealed an ejection fraction of 56% with normal pulmonary artery pressure and no pericardial effusion. She was not able to perform full lung function test as she was not able to blow fully.

We diagnosed her with SLS, as a diagnosis of exclusion, two years after the initial symptoms of dyspnoea. Warfarin was ceased and she started on  $\beta$ -agonist inhaler, which she did not respond to. Subsequently, theophylline was initiated which she did not tolerate due to palpitation and tachycardia. Over the years, she received a prolonged course of moderate to high doses of corticosteroid for refractory lupus nephritis, as well as various second line agents including cyclophosphamide and combination of tacrolimus and mycophenolate mofetil. Unfortunately, she continued to have heavy proteinuria and subsequently developed generalised edema, cardiac failure and worsening of renal function. A repeat renal biopsy revealed lupus nephritis class III with chronicity. Her condition deteriorated and she succumbed to her illness four years after the onset of

dyspnoea. The cause of death was sepsis with multi-organ failure.

## DISCUSSION

Shrinking lung syndrome (SLS) is a rare condition commonly found in patients with SLE. So far, the etiology of SLS remains unknown. Its pathogenesis remains controversial and includes diaphragm dysfunction, phrenic neuropathy or pleural inflammation [4].

Increased SLE disease duration was significantly associated with SLS [3]. However, our patient developed dyspnoea only a year after SLE was diagnosed. The finding of anti-Ro antibodies in various reports was conflicting. Two case series reported that it is found in the majority of patients with SLS (10 of 13 [5] and 6 of 7 patients [6]), while another case series of 31 SLE patients, reported the presence of anti-Ro antibodies in 35% patients only [2]. Seropositivity for anti-RNP had also been reported to be significantly associated with SLS [3]. Our patient tested positive for both anti-Ro antibodies and anti-RNP antibodies.

The main presentation of SLS is dyspnoea, which was reported to be present in more than 98% [2, 5] of patients with SLS. Majority presented with exertional dyspnoea and later progressed to dyspnoea at rest [5], which was the main feature of SLS in our patient and this was one of the basis of her diagnosis. However, the diagnosis of SLS was only made after two years of multiple episodes of dyspnoea. One of the reason for the delayed in diagnosis was failure to recognize the significance of the small lung volumes repeatedly seen in multiple chest radiographs. The other reason was because she had other factors which can explain the dyspnoeic episodes such as pneumonia, serositis and morbid obesity. A delay in diagnosis was also reportedly to be common; with a mean duration of symptoms before the diagnosis of 11±20 months [2].

Our patient had bilateral small lung volumes with raised hemi-diaphragms on serial chest radiographs and fairly normal lung parenchyma on HRCT. The most frequent chest radiograph finding in

SLS was elevated unilateral or bilateral hemidiaphragms [2, 5], with reduced lung volumes being observed in 69% of patients (49 of 71) [2]. The main utility of HRCT was in ruling out the presence of parenchymal lung disease or vascular pathology [2]. The hallmark feature of SLS is restrictive pattern on lung function test [1]. Our patient was not able to perform this test on two separate occasions as she was unable to hold her breath and blow long enough.

Apart from corticosteroid, immunosuppressive agents such as azathioprine, cyclophosphamide, mycophenolate mofetil and methotrexate were used, although effectiveness of the medications were not reported. Rituximab had been used in severe or refractory cases, with effective and good safety profile [2]. SLS is a benign disease with good long-term prognosis, although respiratory failure can occur in some cases [4]. In two studies, 54 of 55 patients were still alive and no patients required home oxygen [2], and clinical improvement were described in 48 of 52 cases [5]. Unfortunately, our patient remained symptomatic despite treatment with various strong immunosuppressants including moderate to high dose corticosteroids.

## CONCLUSIONS

In conclusion, although SLS is a rare condition associated with SLE, its presentation of dyspnoea is very common. Patients may end up with variety of investigations and therapies without a definitive diagnosis. The highlight of this case is, SLS should be considered fairly early in the work-up of an SLE patient who presented with recurrent unexplained dyspnoea. In the end, although her shrinking lungs did not cause her death, it certainly was a contributing factor. More importantly, the shrinking lungs had led to prolonged morbidity for this young lady.

## Conflicts of Interest

Authors declare none.

## Acknowledgements

We would like to thank the Director General of Health Malaysia for his permission to publish this article.

## REFERENCES

1. Hoffbrand BL, Beck ER. 'Unexplained' dyspnoea and shrinking lungs in systemic lupus erythematosus. *Brit Med J*. 1965; 1(5445): 1273-77.
2. Borrell H, Narváez J, Alegre JJ, Castellví I, Mitjavila F, Aparicio M, Armengol E, Molina-Molina M, Nolla JM. Shrinking lung syndrome in systemic lupus erythematosus: A case series and review of the literature. *Medicine*. 2016. <http://dx.doi.org/10.1097/MD.00000000000004626>. Accessed 20 Jan 2017.
3. Allen D, Fischer A, Bshouty Z, Robinson DB, Peschken CA, Hitchon C, El-Gabalawy H, Meyers M, Mittoo S. Evaluating systemic lupus erythematosus for lung involvement. *Lupus*. 2012; 21(12): 1316-25.
4. Carmier D, Diot E, Diot P. Shrinking lung syndrome: recognition, pathophysiology and therapeutic strategy. *Expert Rev Respir Med*. 2011; 5(1): 33-9.
5. Duron L, Cohen-Aubart F, Diot E, Borie R, Abad S, Richez C, Banse C, Vittecoq O, Saadoun D, Haroche J, Amoura Z. Shrinking lung syndrome associated with systemic lupus erythematosus: A multicenter collaborative study of 15 new cases and a review of 155 cases in the literature focusing on treatment response and long-term outcomes. *Autoimmun Rev*. 2016; 15(10): 994-1000.
6. Neves FS, da Silva TH, Paviani G, Zimmermann AF, de Castro GR, Pereira IA. Reinforcing a medical hypothesis with a new question: is there a subgroup of shrinking lungs syndrome that is induced by pleurisy in systemic lupus erythematosus and is this subgroup marked by anti-Ro/SSA? *Clinical Rheumatology*. 2010; 29(7): 777-9.