

JCHS-IQ-01-2017

Case Presentation

A 23-year-old male was referred by his GP to an ENT clinic with a complaint of non-resolving left otalgia for 6 months despite various medications. In addition, he had left ear tinnitus and there was also pain at the left side of his throat. He denied any ear discharge, hearing loss or fever. Examination at the ENT clinic revealed localised tenderness at the region between mastoid tip and angle of mandible. No mass was palpable at that site. Flexible nasolaryngoscopy was entirely normal. Based on the CT images below, what is the most likely diagnosis?

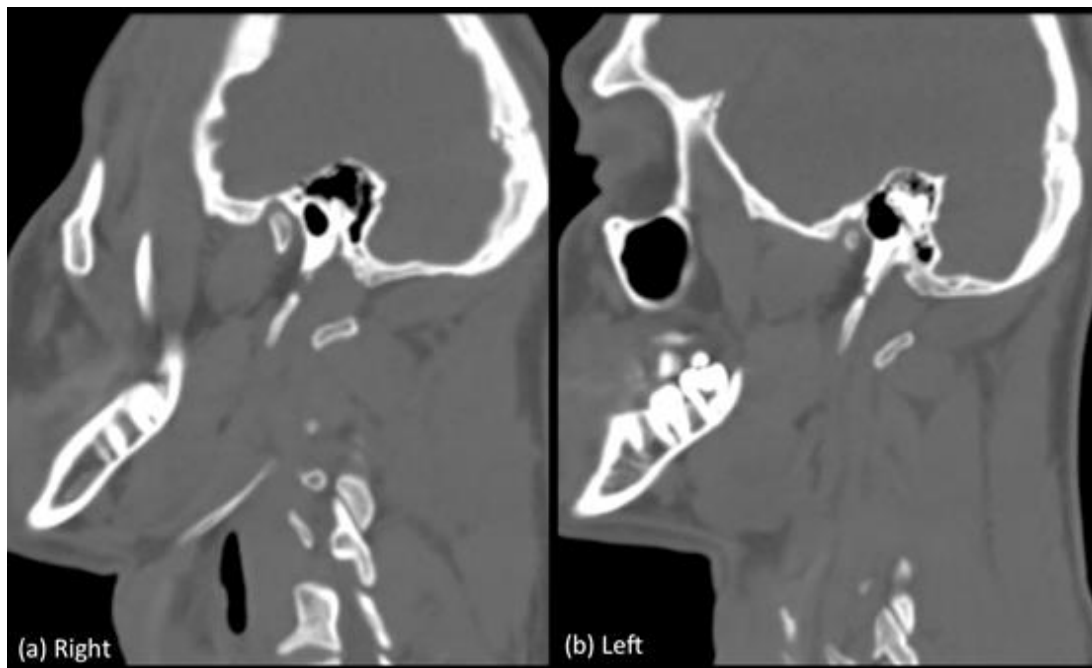


Figure 1 CT sagittal oblique multiplanar reconstruction of the neck

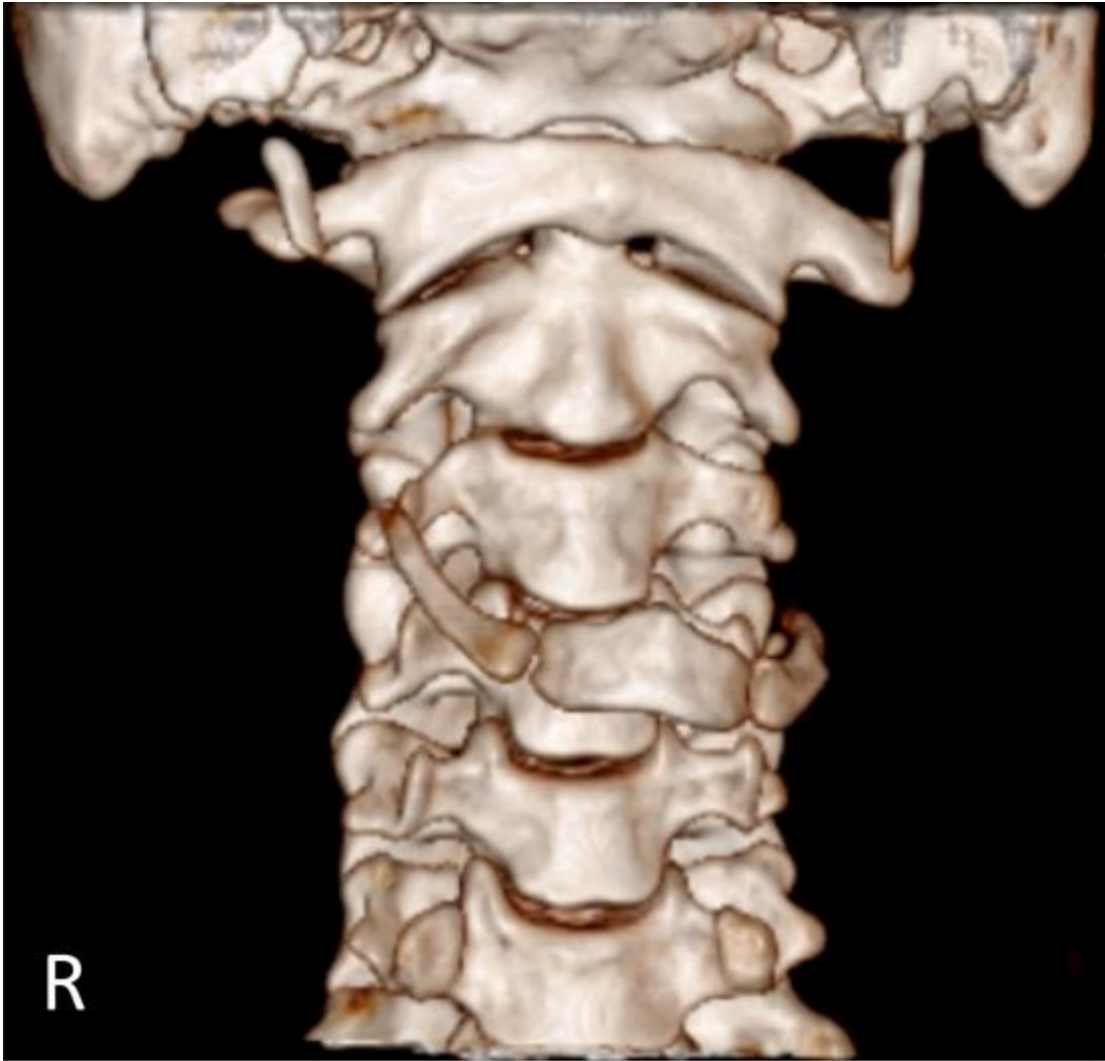


Figure 2 Volume Rendering Technique (VRT) reconstruction of the CT