

## Outcome of Chiropractic Therapy in Idiopathic Scoliosis – A Preliminary Study

Syahirah Zeti Azham<sup>1</sup>, Nur Firzanie Kamaruddin<sup>1</sup>, Ezreen Elia Izzaty Afindi<sup>1</sup>, Lyanna Annura Sallehudin<sup>1</sup>, Mohd Nizam Haron<sup>2</sup>, Khairul Nizam Rozali<sup>1</sup>, Sabrilhakim Sidek<sup>1</sup>

<sup>1</sup> Faculty of Medicine, Universiti Teknologi MARA, Sungai Buloh, Selangor, Malaysia

<sup>2</sup> School of Animal Science, Faculty of Bioresources and Food Industry, Universiti Sultan Zainal Abidin, Terengganu, Malaysia

### Received

31<sup>st</sup> January 2017

### Received in revised form

15<sup>th</sup> April 2017

### Accepted

27<sup>th</sup> November 2017

### Corresponding author:

**Dr. Sabrilhakim Sidek,**

Medical Imaging Unit,

Faculty of Medicine,

Universiti Teknologi MARA (UiTM),

Sungai Buloh Campus,

47000 Sungai Buloh, Selangor,

Malaysia.

Tel: +60166267020

Email: sabrilhakim@salam.uitm.edu.my

### ABSTRACT

**Introduction:** The purpose of this study is to retrospectively report the results of scoliosis patients who underwent chiropractic therapy and to evaluate their outcome by looking at the potential to alter the natural progression of scoliosis after therapy. **Methods:** Retrospective data collection was conducted at a private chiropractic centre in Kuala Lumpur. The data was collected from patients between the ages of 16 to 19 years old. A total of eight patients with 14 scoliotic curvatures (six thoracic, six lumbar and two thoracolumbar), who met the inclusion criteria, were selected as subjects for this study. All subjects received the same chiropractic therapy program. The outcome of the therapy was assessed by measuring the Cobb's angle on the erect spine as captured on an x-ray. The Cobb's angle was measured at the first presentation (to establish a baseline) after 6 and 24 months of therapy. **Results:** The mean baseline Cobb's angle for thoracic, lumbar and thoracolumbar scoliosis were  $30.7^\circ \pm 19.4^\circ$ ,  $31.7^\circ \pm 12.3^\circ$  and  $25.0^\circ \pm 18.4^\circ$  respectively. After 24 months of chiropractic therapy, there was no discernible effect on the magnitude of the Cobb's angles on the subjects overall. **Conclusion:** Our study showed no significant reduction in spine curvature in patients with scoliosis using chiropractic therapy after 24 months.

**KEYWORDS:** Chiropractic therapy, Scoliosis, Cobb's angle, Spine

## INTRODUCTION

According to the Scoliosis Research Society, scoliosis is defined as a lateral curvature of the spine exceeding  $10^\circ$  as measured using the Cobb's angle method on the erect spine radiograph [1]. Scoliosis can be due to unknown etiology (Idiopathic scoliosis) or due to a secondary underlying disease such as an inherited disorder of connective tissue, neurological or musculoskeletal diseases [2] and can be identified through radiographic and clinical examination.

Idiopathic scoliosis can be classified based on the age of the patient when the scoliosis was first identified. Infantile scoliosis which has an onset before the age of three years, accounts for less than 1% of all scoliosis cases. Juvenile scoliosis which is first detected between the ages of three and puberty, accounts for about 12 to 21% of all idiopathic scoliosis cases. Adolescent scoliosis accounts for the majority of idiopathic scoliosis cases, between the ages of 10 years and skeletal maturity [3].

The progression of the deformity of the spine is the most important problem encountered in scoliosis and its associated collateral effects. There are several factors influencing the risk of progression in scoliosis such as, i) growth potential of the patients in terms of skeletal maturity and age of menarche, ii) magnitude of the curvature, and iii) types of curvature. In addition, the risk of progression in scoliosis is also greater in women compared to men [2].

Idiopathic scoliosis can be managed via a few modes of treatments such as bracing, surgical intervention and chiropractic therapy. Typically, chiropractic therapy for scoliosis consists of spinal manipulation, electrical stimulation, and active exercises.

The chiropractic care in scoliosis is divided into 3 major steps which are, i) applying force in a specific direction to the body which causes diversified chiropractic adjustments, ii) cervical and lumbar traction and iii) electrical muscle stimulation therapy

(EMS). Step i) above results in a change of position and motion of spinal bones or other joints of the body. Force is applied with hands. A popping noise may be heard, resulting from gas and lubricating fluids in the spinal joints shifting. Usually the patients will receive treatment on a special chiropractic table designed with several parts that can be moved to assist the chiropractor in performing the adjustments. Areas requiring chiropractic adjustments were determined by postural distortions, x-ray analysis, compromised range of motion, and restricted joint play and pain. Step ii) required patients to lie prone for 10 minutes on a dedicated chiropractic table machine. Eventually step iii) is applied as the last step. Skin electrodes are placed on the muscles between the ribs on the side of the chest, directly under the arm. EMS is often used on injured muscles or stroke rehabilitation, improvement of the health of damaged tissue, and chronic muscle pain relief. Advice was also given by the chiropractor to the patients to encourage home exercise to avoid any asymmetrical development and deterioration of the curve. However, the patients' application of this home exercise could not be monitored closely. The home exercise includes yoga and swimming.

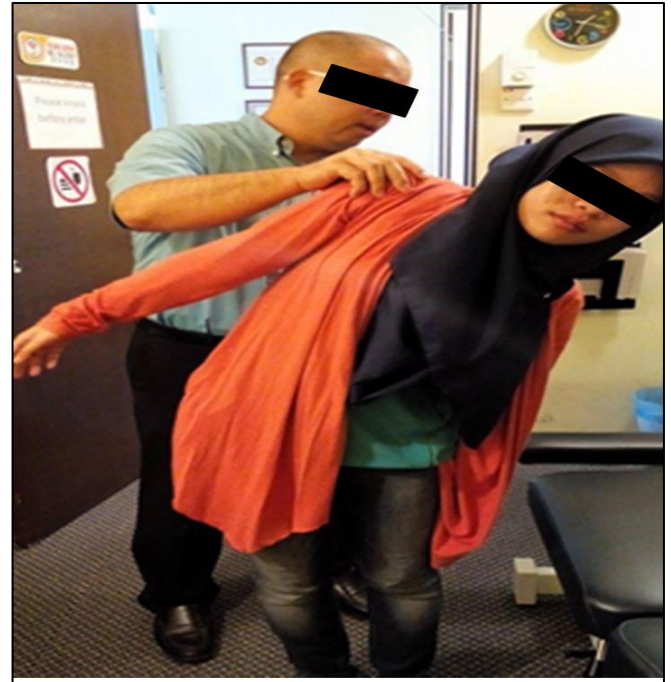
Radiological investigation i.e. spine x-rays were performed at certain time durations principally to reduce the patient's exposure to radiation without any significant loss of diagnostic information throughout the chiropractic therapy. This is supported by international consensus of scoliosis radiographic monitoring [4].

In this study, we evaluated the results of patients, who underwent chiropractic therapy, and to look for the outcome of this therapy method to alter the natural progression of scoliosis.

## METHODS

A retrospective study was conducted in a private chiropractic centre in Kuala Lumpur. Study approval was obtained from the institutional review board and the respective centre. The chiropractic care was provided by 2 licensed chiropractors with 13 years and 2 years of experience respectively who specialized in Diversified and Drop techniques, sports injuries, physiotherapy and scoliosis treatment. These

two licensed chiropractors together with two supporting staff were interviewed regarding the patients' preparations prior to the procedure, techniques, possible complications arising and choices of patients (Figure 1).



**Figure 1** Demonstration of physical examination to one of the authors that is essential in the chiropractic therapy

Eight scoliotic patients with initial scoliosis curves of less than  $40^\circ$  was studied. Patients with Cobb's angle exceeding  $40^\circ$  were not included as these cases were considered potential candidates for surgery and therefore will be referred to the hospital for further management [5, 6]. From eight patients, six of them had two scoliotic curves i.e. at the thoracic and lumbar spine, whereas two of them had only one scoliotic curve at the thoracolumbar region. In this study, we based the sample quantity on the number of scoliotic curves detected. Therefore, there were a total of 14 scoliotic curves in this study sample which consisted of six thoracic, six lumbar and two thoracolumbar scoliotic curves. The age of the patients ranged from 16-19 years old, which consisted of three males and five females. Our inclusion criteria also included subjects with no comorbid conditions and had no significant history of chronic diseases and had never undergone spinal surgery previously.

Erect spine x-ray assessments were done at the same centre with the same chiropractors to reduce bias

in the measurement of the Cobb's angle. Each spine x-ray was subcategorized into 1 of 3 groups based on curvature type: thoracic (Group 1), lumbar (Group 2) and thoracolumbar (Group 3).

For each patient, the initial Cobb's angle was measured at his or her first presentation to the chiropractic centre. This measurement served as the control value for each patient, and each patient served as his or her own control. Patients were then required to come weekly for their chiropractic therapy and a follow up spine x-ray examination was performed after 6 months. Final data collection on the Cobb's angle was obtained from these patients after 24 months of therapy. Therefore, three different Cobb's angle measurements were obtained for each scoliotic curvature, which were labelled as Cobb 1, Cobb 2 and Cobb 3 in this study. Cobb 1 represents the baseline or initial Cobb's angle; Cobb 2 represents Cobb's angle after 6 months of therapy; Cobb 3 represents Cobb's angle after 24 months of therapy.

Statistical analyses were performed using one-way repeated measure ANOVA followed by Bonferroni post Hoc test (SPSS Version 19.0, SPSS Inc., Chicago, IL, USA). A *p* value of < 0.05 was considered statistically significant.

## RESULTS

All patients ranged in age between 16 and 19 years, with mean age of  $17.5^\circ \pm 0.9^\circ$  years. The patients consisted of 3 males (37.5%) and 5 females (62.5%). The mean baseline Cobb's angle (Cobb 1) for thoracic, lumbar and thoracolumbar scoliotic curves were  $30.7^\circ \pm 19.4^\circ$ ,  $31.7^\circ \pm 12.3^\circ$  and  $25.0^\circ \pm 18.4^\circ$  respectively. The mean Cobb's angles after 6 months therapy (Cobb 2) for thoracic, lumbar and thoracolumbar scoliosis were  $37.4^\circ \pm 18.3^\circ$ ,  $32.0^\circ \pm 16.4^\circ$  and  $26.5^\circ \pm 9.2^\circ$  respectively. The mean Cobb's angles after 24 months therapy (Cobb 3) for thoracic, lumbar and thoracolumbar scoliosis were  $34.7^\circ \pm 20.6^\circ$ ,  $33.3^\circ \pm 17.5^\circ$  and  $23.5^\circ \pm 6.4^\circ$  respectively.

In the thoracic scoliosis group, the Cobb's angle significantly increased after 6 months and 24 months of therapy ( $p=0.02$  and  $0.01$  respectively) i.e. between Cobb 1 and Cobb 2 groups; and in between Cobb 1 and Cobb 3 groups.

**Table 1** Mean ( $\pm$ SD) of Cobb 1, 2 and 3 for thoracic, lumbar and thoracolumbar curve type as well as the respective *p*-values

Curve type (group)	Cobb 1 ( $^\circ$ ) (baseline or initial Cobb's angle)		Cobb 2 ( $^\circ$ ) (Cobb's angle after 6 months of therapy)		Cobb 3 ( $^\circ$ ) (Cobb's angle after 24 months of therapy)		<i>p</i>
	n	Mean $\pm$ SD	n	Mean $\pm$ SD	n	Mean $\pm$ SD	
Thoracic (group 1)	6	30.7 $\pm$ 19.4	6	37.4 $\pm$ 18.3	6	34.7 $\pm$ 20.6	0.02* 0.01#
Lumbar (group 2)	6	31.7 $\pm$ 12.3	6	32.0 $\pm$ 16.4	6	33.3 $\pm$ 17.5	NS
Thoraco-lumbar (group 3)	2	25.0 $\pm$ 18.4	2	26.5 $\pm$ 9.2	2	23.5 $\pm$ 6.4	NS

Notes: Data was expressed as mean ( $\pm$ SD) and analysed using one-way repeated measure ANOVA followed by Bonferroni post Hoc test. n=number of curvatures; SD=standard deviation. \*=*p* value for comparison between Cobb 1 & 2; #=*p* value for comparison between Cobb 1 & 3; NS=not significant ( $p>0.05$ ).

There was no significant difference in the *p*-value ( $p>0.05$ ) between the Cobb's angle after 6 months and 24 months of therapy although there was a reducing trend in the mean value. No significant difference ( $p>0.05$ ) was observed in the lumbar and thoracolumbar scoliosis groups after 6 and 24 months of chiropractic therapy. The mean ( $\pm$ SD) of Cobb 1, 2 and 3 for thoracic, lumbar and thoracolumbar curve type as well as the *p*-values are shown in Table 1.

## DISCUSSION

From our data, we selected eight patients from a private chiropractic centre in Kuala Lumpur who had been under treatment for 24 months. Three sites of curves were assessed, the thoracic, lumbar and thoracolumbar curves. Six out of eight patients had curves at the thoracic and lumbar regions and two patients at the thoracolumbar region. Based on our findings, there was a spurious increase in the Cobb's angle for the thoracic scoliosis group after 6 months and 24 months of therapy. Although there was a reduction of the mean Cobb's angle between 6 months and 24 months of therapy, the trend was not significant. Aside from that, there was no significant difference in the Cobb's angle measured for the lumbar and thoracolumbar scoliosis groups throughout the duration of the therapy. Our findings corroborated with a previous study done by

Lantz C et al. and Skargren EI et al. which showed no difference in outcome could be detected, nor in subgroups defined as duration, history, or severity in view of scoliosis or back pain [7, 8]. Furthermore, a review article by Shah SA concluded that, the non-operative treatment of idiopathic scoliosis outcomes were still controversial [9].

In addition to the in-clinic chiropractic therapy, patients were also advised to perform strengthening exercises at home. According to a research regarding rehabilitation exercises for scoliosis therapy done by Wnuk B et al. [10] and supported by a study performed by Cheon M et al. [11], spine and pelvic muscle strengthening exercises can prevent the progression of scoliosis in teenagers. We believe this factor could also play an important role and contribute to the effectiveness and improvement of the scoliotic curve. However, in this study we could not evaluate this factor. This could be the contributing factor to the significant difference between Cobb 1 and Cobb 2 as well as Cobb 1 and Cobb 3 angles measurement in thoracic scoliosis where patients may not be compliant to home exercise therapy [12].

Other limiting factors in our study were that we only obtained data on Cobb's angle from a small sample size, which could be insufficient to determine the efficacy of the therapy. In a study performed by Morningstar MW with a larger sample size, there were multiple parameters used to assess the outcomes at the end of active treatment. These included pain scale, respiratory and functional rating index for disability, in addition to radiographic assessment. This study showed that there were significant radiographic, self-rated, and physiologic benefits after therapy [13].

Chiropractic therapy has a few benefits whereby it helps in relieving joint pain, discomfort, and improves posture. Goertz et al. stated that compared to the standard medical care, chiropractic therapy provides better improvements in lowering pain and increasing physical functioning for both males and females in the range of 18-35 years of age with acute lower back pain [14].

Therefore, studies involving additional multiple parameters, larger sample sizes, as well as a longer duration of therapy should be performed in the

future to elucidate better outcomes of chiropractic therapy.

## CONCLUSION

Our study showed no significant reduction in spine curvature in patients with scoliosis using chiropractic therapy after 24 months.

## Conflict of Interest

Authors declare none.

## Acknowledgement

We would like to acknowledge UiTM Faculty of Medicine for their support and guidance throughout this study. We would also like to thank the chiropractic centre for their help in gathering the data and procedure demonstration.

## REFERENCES

1. Kane WJ. Scoliosis prevalence: a call for a statement of terms. *Clin Orthop Relat Res.* 1997; 126: 43–6.
2. Joseph AJ, Benjamin A. Scoliosis: Review of diagnosis and treatment. *Paediatr Child Health.* 2007; 12(9): 771-6.
3. Segal LS, Vanderhave KL. Adolescent idiopathic scoliosis: current concepts of surgical management. *Current Opinion in Orthopaedics.* 2006; 17(6): 493-8.
4. Knott P, Pappo E, Cameron M, Rivard C, Kotwicki T, Zaina F, Wynne J, Stikeleather L, Bettany-Saltikov J, Grivas TB, Durmala J. SOSORT 2012 consensus paper: reducing x-ray exposure in pediatric patients with scoliosis. *Scoliosis.* 2014; 9(1): 4.
5. Kim K-D, Hwangbo P-N. Effects of the Schroth exercise on the Cobb's angle and vital capacity of patients with idiopathic scoliosis that is an operative indication. *J Phys Ther Sci.* 2016; 28(3): 923-6.
6. Weiss H-R, Goodall D. Rate of complications in scoliosis surgery – a systematic review of the Pub Med literature. *Scoliosis.* 2008; 3: 9.

7. Lantz C, Chen J. Effect of chiropractic intervention on small scoliotic curves in younger subjects: A time-series cohort design. *J Manipulative Physiol Ther.* 2001; 24(6): 385-93.
8. Skargren EI, Oberg BE, Carlsson PG, Gade M. Cost and effectiveness analysis of chiropractic and physiotherapy treatment for low back and neck pain: six-month follow-up. *Spine.* 1997; 22(18): 2167-77.
9. Shah SA. Nonoperative treatment for adolescent idiopathic scoliosis. *Seminars in Spine Surgery.* 2015; 27(1): 27-32.
10. Wnuk B, Frackiewicz J, Durmala J, Czernicki K, Wadolowski K. Short-term effects of combination of several physiotherapy methods on the respiratory function - a case report of adolescent idiopathic scoliosis. *Stud Health Technol Inform.* 2012; 176: 402-6.
11. Cheon M, Park J, Lee Y, Lee J. Effect of chiropractic and lumbar exercise program on lumbar muscle strength and Cobb's angle in patients with scoliosis for u-Healthcare. *EURASIP J Wirel Commun Netw.* 2013; 132: 1-6.
12. Milroy P, O'Neil G. Factors affecting compliance to chiropractic prescribed home exercise: a review of the literature. *J Can Chiropr Assoc.* 2000; 44(3): 141
13. Morningstar MW. Outcomes for adult scoliosis patients receiving chiropractic rehabilitation: a 24-month retrospective analysis. *J Chiropr Med.* 2011; 10(3): 179-84.
14. Goertz CM, Long CR, Hondras MA, Petri R, Delgado R, Lawrence DJ, Owens EF, Meeker WC. Adding chiropractic manipulative therapy to standard medical care for patients with acute low back pain: results of a pragmatic randomized comparative effectiveness study. *Spine.* 2013; 38(8): 627-34.