

### Improper Technique of Eye Drop Instillation Leading to Corneal Ulcer in a Visually Impaired Glaucoma Patient

Azhan A<sup>1,2</sup>, Zunaina E<sup>2</sup>, Khairidzan MK<sup>1,3</sup>, Fatimah SS<sup>1</sup>, Ahmad-Nurfahmi Akhtar Ali<sup>1,3</sup>

1 Department of Ophthalmology, Hospital Tengku Ampuan Afzan, Kuantan, Pahang, Malaysia

2 Department of Ophthalmology, School of Medical Sciences, Health Campus, Universiti Sains Malaysia, Kubang Kerian, Kelantan, Malaysia

3 Department of Ophthalmology, International Islamic University Malaysia, Kuantan, Pahang, Malaysia

#### Received

14<sup>th</sup> May 2018

#### Received in revised form

19<sup>th</sup> June 2018

#### Accepted

23<sup>rd</sup> July 2018

#### Corresponding author:

**Ahmad Nurfahmi Akhtar Ali,**

Department of Ophthalmology,

Kulliyyah of Medicine,

International Islamic University

Malaysia,

25200 Kuantan,

Pahang, Malaysia

Tel: +60176502652

Fax: +09-5716785

Email: drfahmiophthal@gmail.com

#### ABSTRACT

We report a case of visually impaired glaucoma patient with long term use of topical glaucoma medications presented with a corneal ulcer due to the improper technique of eye drop instillation. A 70-year-old gentleman with advanced primary open angle glaucoma (POAG) on his right eye and absolute glaucoma on his left eye, presented with painful redness and purulent discharge of the right eye for two weeks. He was using four types of topical glaucoma medication on his right eye since failed trabeculectomy two years ago. His right eye vision was 6/24 and painless blindness of the left eye before the presentation. He was administering all the medications himself despite his current vision status. Right eye examination showed visual acuity of 3/60 with clinical features of corneal ulcer. During the observation of his eye drop instillation technique, he consistently touched the tip of the bottle to his right cornea. The corneal contact area corresponded to the corneal ulcer area and size. In addition to this, the culture result obtained from both corneal ulcer and the bottles' tips yielded similar microorganism which was *Staphylococcus aureus*. After an intensive course of topical antibiotics treatment, the corneal ulcer healed with a scar and the vision improved to 6/24 from 3/60. Although this incident is rare, it is crucial for the treating physicians to address the issue properly and co-manage these patients with pharmacists and nursing staffs as well as to seek support from the caretakers to prevent this blinding complication.

**KEYWORDS:** corneal ulcer, glaucoma medication, eye drop instillation technique

#### INTRODUCTION

In elderly, poor visual acuity resulting from primary open-angle glaucoma (POAG) in the presence of other comorbidities such as arthritis, stroke, and neuropathy pose extra challenges to physician and patient in regards to treatment compliant as well as efficiency [1]. Long-term use of topical glaucoma medications is known to be associated with complications especially ocular surface diseases [2]. The ocular surface is also vulnerable to injury and with poor eye drop instillation technique may lead to further adverse consequences [2]. We report a case of visually impaired and advanced POAG patient with long term use of topical glaucoma medications presented with a corneal ulcer due to improper technique of eye drop instillation.

#### CASE PRESENTATION

A 70-year-old gentleman who was diagnosed with right eye advanced POAG and left eye absolute glaucoma presented with right eye redness for two weeks.

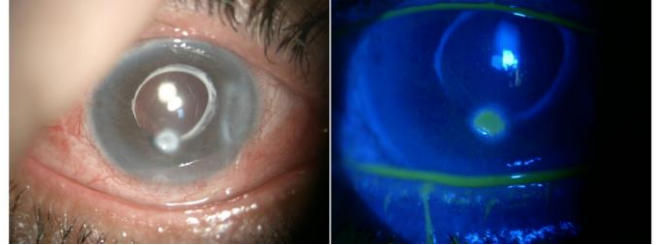
He was diagnosed to have bilateral POAG by a private center three years ago when he presented with bilateral painless, progressive blurring of vision. At the same time, he also was diagnosed to have right eye cataract, and cataract operation was done. He was referred for further management of glaucoma a year later in view of poor intraocular pressure (IOP) control despite maximum anti-glaucoma drugs. At the initial presentation to our hospital, his right eye vision was 6/24 and non-perception of light in the left eye. The IOP was 18 mmHg in the right eye and 50 mmHg in the left eye.

The optic disc was 0.8 cup disc ratio (CDR) in the right eye and fully cupped in the left eye. Humphrey visual field test (10-2) revealed a tunnel vision pattern without a macular split in the right eye. Augmented trabeculectomy was performed in the right eye, however it was only functioning for less than one year. Due to failed trabeculectomy, the patient opted for conservative management subsequently. In view of non-perception of light in the left eye, cyclodiode was performed a year later to control the IOP. In the past two years, he had been self-administering four types of glaucoma medication drops to his right eye without noticeable complications and complaints. The four types of glaucoma medication drops were prostaglandin analogue (Xalatan, Pfizer, USA), dorzolamide (Trusopt, Santen Pharma, Japan), beta-blocker (Timolast, Alcon, USA), and brimonidine tartrate (Alphagan P, Allergan, Ireland). He also suffered from type 2 diabetes mellitus and was on two oral hypoglycaemic agents. His glycaemic control was good with a HbA1c value of 7.0%.

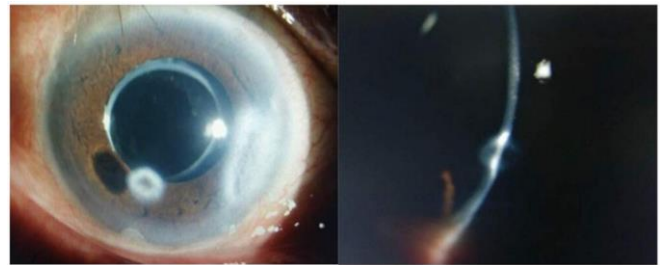
Upon his latest follow-up, he complained of right eye redness for two weeks. It was associated with pain purulent discharge. The vision of the right eye was progressively worsening. Otherwise, there was no history of prior bleb leakage, trauma or contact lens wear or even contact with a patient who had active eye infections.

On examination, the right eye vision was 3/60 and not improved with pinhole test. The left eye had no perception of light and positive relative afferent pupillary defect. Examination of the right eye showed mildly swollen and hyperemic eyelid. The conjunctiva was injected and had mucopurulent discharge especially in the inferior fornix. There was a paracentral whitish anterior stromal infiltrates on the cornea at 7 o'clock, measured 2 mm horizontally and 1.5 mm vertically. The stromal infiltrate was associated with an overlying epithelial defect and there was localized pan-stromal edema surrounding the lesion (Figure 1). Trabeculectomy bleb was shallow but not opacified with no sign of blebitis. The Siedel's test of the bleb was negative. The anterior chamber was deep with cells of one plus with no hypopyon or fibrin. There was a clear posterior chamber intraocular lens with 15 mmHg IOP. Fundus examination showed

a pale optic disc with 0.8 CDR. There were multiple small drusen on the mid-peripheral retina and macula was normal. The left eye examination showed normal anterior segment with 20 mmHg IOP. The left fundus showed a pale disc with fully optic disc cupping.



**Figure 1** Right eye showed corneal infiltrate (left) with an overlying epithelial defect with surrounding epithelial edema (right)



**Figure 2** Healed ulcer with a complete absence of stromal edema and fibrosis taking place. A mechanical stromal thinning remained resulting from the bottle tip injury

Right eye conjunctival swab for culture and sensitivity revealed *Staphylococcus aureus*, but corneal gram stain did not reveal any organism. Due to this peculiar presentation of the corneal ulcer, the administration of topical medication technique was reassessed. It was noted that the tip of the eye drop bottle had repetitively touched the cornea each time the drop was instilled. Then, all the four bottles tips were sent for culture. The culture grew the colony of *Staphylococcus aureus* from two of the bottle tips. With evidence of the corneal ulcer characteristic, which was well defined, deep stromal lost with a clean base and slight inferiorly located in addition to a similar organism cultured from both the ulcer and the bottle tips; we concluded it was strongly a trauma related. It was a repetitive trauma occurred during drugs instillation.

He was admitted for close monitoring and intensive eye care. The right eye was started on intensive topical ceftazidime (5%) and gentamicin (0.9%) along with ointment fusidic acid. After a week of treatment, the stromal infiltrates resolved and

corneal defect re-epithelialized. His right eye vision improved to 6/24. Upon discharge, his topical glaucoma medications were reduced to three types namely prostaglandin analogue, brimonidine tartrate, and a combination medication (travoprost and timolol maleate: DuoTrav by Alcon) together with topical antibiotics (ceftazidime and gentamicin). The administration of eye drops was taken over by his family members after a thorough counseling session with pharmacist and nursing staffs. The correct instillation technique and hygiene were reemphasized to the patient and caretakers.

## DISCUSSION

The long-term use of glaucoma eye drop medications especially those containing preservatives with improper instillation technique and handling of the eye drops were reported to be associated with many adverse effects [2, 3]. Ocular surface irritation, corneal and conjunctival inflammation and infection, and inadequate response to treatment represent some of them [4]. In eyes that have previous glaucoma surgery, poor handling of eye drops may lead to contamination which can predispose to bleb-related infections [4].

Most of the elderly patients who are on chronic topical glaucoma medication, they administered the eye drops by themselves without any assistance. [5, 6]. Interestingly, Stone et al. [6] and Hennessy et al. [1] highlighted that 80% of the patients believed that they have no trouble with instilling the eye drops or denied touching the eyes with the bottle tip prior participation in their study. Based on their studies via video recording, they revealed that 20-60% of patients had inadvertently touched part of the eye either the ocular surface, lids or eyelashes while attempting to administer their eye drops [1, 6, 7]. Similarly, another study also reported that less than 40% of them able to instill the medications correctly [5]. Stone et al. [6] who evaluated experienced patients with instillation of topical glaucoma medication found that only 21.9 to 31% were able to instill a single drop without touching the eye. Based on these reports, it is not surprising that our patient who has advanced glaucoma had difficulties with instillation of four different topical medications.

Age of more than 60 years was highlighted as significantly associated with poorer instillation technique [1, 8]. This may be due to associated comorbidities such as arthritis, stroke, hand tremor, and neuropathy [1]. Vision status is also an important factor that influences the success of eye drops instillation [1]. This finding correlates to our patient who only left with one seeing the glaucomatous eye. Dietlein et al. [7] found that vision in the better eye correlates with the ability to instill eye drops accurately. In addition to this, a mean deviation (MD) of more than -6.00 in a standard visual field test (which was also present in our patient), associated with poorer eye drops instillation success [1, 8]. Other factors that help to determine the success of eye drops instillation are education level, handgrip strength, familiarity with eye drop container and size of eye drop container [1, 6, 7].

Poor instillation technique and poor hygiene during eye drop instillation may lead to bottle tip contamination. This was shown by Geyer et al. [9] who reported from their observations of 109 glaucoma patients; they found that almost 31% of the medications were contaminated especially at the bottle tip. The gram-positive organism was cultured from 91% of the medication's bottles, of which 69% were *Staphylococcus epidermidis* [9]. A pathogenic gram-negative organism such as *Serratia marcescens*, *Moraxella* species, and *Pseudomonas* species was found in 6% of the medications [9]. Wasson et al. [10] reported seven cases of severe keratitis associated with contaminated topical medications. *Pseudomonas aeruginosa*, *Serratia marcescens*, and *Proteus mirabilis* were the organisms involved [10]. In this case report, *Staphylococcus aureus* was cultured from two out of four bottles' tip. Poor hygiene during instillation of eye drops may also result in contamination of the medications. From observation of recorded video by Stone et al. [6], only 1.7% of patients performed hand washing before eye drops instillation. Hence, we suggest all treating physicians emphasize on good hand hygiene during the consultation and to evaluate the proper technique regularly.

Long-term use of topical glaucoma medication, especially with the preservative such as benzalkonium chloride [BAK], is associated with

ocular surface disruption. This may expose the cornea to injury and disrupt the corneal healing process. Preservative in topical glaucoma medications serves essential purposes which are to inhibit microbial growth and preserve the active medication ingredient [11]. However, it is also responsible for ocular side effects through several mechanisms, namely, direct toxicity to the conjunctival and corneal epithelium, disruption of tear film stability and ocular immunological reaction [3]. BAK was shown to promote activation of lipooxygenases and synthesis and secretion of inflammatory mediators and cytokines [3]. This was evident from conjunctival biopsies of 124 patients with long-term glaucoma medication which revealed numerous inflammatory cells in the epithelium and substantia propria [12]. Long-term use of topical glaucoma medication also associated with the destruction of goblet cells in the conjunctiva, reduced aqueous production and break in the superficial lipid layer [2, 12, 13]. Corneal epithelial disruption by BAK also causes the cornea epithelium failed to maintain substantial adhesion to basement membrane [13]. These ocular findings appeared to be more prevalent in the patient using more than one topical eye drops for more than three years [12]. Our patient has been using four types of topical eye drop for two years. Apart from ocular surface disruption, corneal sensitivity also reduced in patient with long-term use of topical glaucoma medication regardless of whether it is preservative or non-preservative [3]. The reduction of corneal sensitivity is due to reduced number and density of sub-basal nervous plexus observed in a study by Martone et al. [3]. Ocular surface condition and corneal sensitivity are important factors to maintain a healthy corneal surface.

Ocular surface disruption and reduced corneal sensitivity from long-term use of topical glaucoma medication may lead to corneal injury. Besides, repetitive trauma to the cornea by improper instillation technique and contaminated bottle tip increase the risk of subsequent bacterial corneal infection [9, 10, 14]. Although the exact rate of corneal disease associated with topical glaucoma medication eye drop instillation is still not established, the consequences may worsen the vision status of a patient who is already suffering from visual impairment. Thus, measures should be

taken by treating physician to instruct patients of a proper instillation technique, and this can be in the form of direct counseling, video demonstration or even in a written instruction [15]. We suggest an objective evaluation on the technique to be performed especially in patients more than 60 years old, advanced visual field defect, had prior glaucoma surgery and those require more than two bottles of eye drops including adjunctive eye drops such as artificial tears or topical antibiotics. The Glaucoma Medication Self-efficacy Questionnaire can be employed for this purpose [5]. This questionnaire contains two subscales and one of which is a 6-item eye drop technique self-efficacy scale which strongly correlates with a videotaped eye drop technique [5]. This will provide a guide to the treating physician to identify barriers and to educate patients on a proper eye drop instillation technique [5]. For a patient with a physical or mental disability, support from dedicated caretakers is essential [15]. Combination therapy can also be instituted to reduce the number of eye drops per day provided availability and affordability of the medications. The utilization of medicines without preservative and adequate treatment of ocular surface disease in a patient with long-term topical glaucoma medication may also help to reduce the incidence of ocular trauma and infections [12, 13]. Finally, frequent follow-up and re-education during each visit may also improve on the patient instillation technique [15]. The aim is to highlight proper instillation technique including proper hand hygiene and proper handling of the medications.

## CONCLUSION

Visually impaired patients due to advance glaucoma are susceptible to ocular injury resulting from long term use of topical medications which may lead to blinding complication. Therefore, it is the responsibility of the treating ophthalmologist to address the issue properly and co-manage these patients with appropriate healthcare workers. More importantly, support from the caretakers is also vital not just to prevent this complication but also to improve the treatment efficacy.

## Conflict of Interest

Authors declare none

## Acknowledgement

Ophthalmologists and staffs of Ophthalmology Department, Hospital Tengku Ampuan Afzan (HTAA) Kuantan, Clinical Research Centre, HTAA Kuantan.

## REFERENCES

1. Hennessy AL, Katz J, Covert D, Protzko C, Robin AL. Videotaped evaluation of eyedrop instillation in glaucoma patients with visual impairment or moderate to severe visual field loss. *Ophthalmology*. 2010; 117(12): 2345-52.
2. Baudouin C, Renard JP, Nordmann JP, Denis P, Lachkar Y, Sellem E, Rouland JF, Jeanbat V, Bouée S. Prevalence and risk factors for ocular surface disease among patients treated over the long term for glaucoma or ocular hypertension. *Eur J Ophthalmol*. 2013; 23(1): 47-54.
3. Martone G, Frezzotti P, Tosi GM, Traversi C, Mittica V, Malandrini A, Pichierri P, Balestrazzi A, Motolese PA, Motolese I, Motolese E. An in vivo confocal microscopy analysis of effects of topical antiglaucoma therapy with preservative on corneal innervation and morphology. *Am J Ophthalmol*. 2009; 147(4): 725-35.
4. Tatham A, Sarodia U, Gatrad F, Awan A. Eye drop instillation technique in patients with glaucoma. *Eye*. 2013; 27(11): 1293-8.
5. Sleath B, Blalock S, Covert D, Stone JL, Skinner AC, Muir K, Robin AL. The relationship between glaucoma medication adherence, eye drop technique, and visual field defect severity. *Ophthalmology*. 2011; 118(12): 2398-402.
6. Stone JL, Robin AL, Novack GD, Covert DW, Cagle GD. An objective evaluation of eyedrop instillation in patients with glaucoma. *Arch Ophthalmol*. 2009; 127(6): 732-6.
7. Dietlein TS, Jordan JF, Lüke C, Schild A, Dinslage S, Krieglstein GK. Self - application of single - use eyedrop containers in an elderly population: comparisons with standard eyedrop bottle and with younger patients. *Acta Ophthalmol*. 2008; 86(8): 856-9.
8. Kholdebarin R, Campbell RJ, Jin YP, Buys YM, Group CCS. Multicenter study of compliance and drop administration in glaucoma. *Can J Ophthalmol*. 2008; 43(4): 454-61.
9. Geyer O, Bottone EJ, Podos SM, Schumer RA, Asbell PA. Microbial contamination of medications used to treat glaucoma. *Br J Ophthalmol*. 1995; 79(4): 376-9.
10. Wasson PJ, Boruchoff SA, Schein OD, Kenyon KR. Microbial keratitis associated with contaminated ocular medications. *Am J Ophthalmol*. 1988; 105(4): 361-5.
11. Yee RW. The effect of drop vehicle on the efficacy and side effects of topical glaucoma therapy: a review. *Curr Opin Ophthalmol*. 2007; 18(2): 134-9.
12. Broadway DC, Grierson I, O'Brien C, Hitchings RA. Adverse effects of topical antiglaucoma medication: I. The conjunctival cell profile. *Arch Ophthalmol*. 1994; 112(11): 1437-45.
13. Ichhpujani P, Ramasubramanian A. Ocular surface changes with long-term topical antiglaucoma medications. *J Curr Glaucoma Pract*. 2009; 3(3): 19-26.
14. Mayo M, Schlitzer R, Ward M, Wilson L, Ahearn D. Association of Pseudomonas and Serratia corneal ulcers with use of contaminated solutions. *J Clin Microbiol*. 1987; 25(8): 1398-400.
15. Kulkarni SV, Damji KF, Buys YM. Medical management of primary open-angle glaucoma: Best practices associated with enhanced patient compliance and persistence. *Patient Prefer Adherence*. 2008; 2: 303.