

Suspected Hand, Foot and Mouth Disease (HFMD) in an Adult: An Uncommon but Important Infectious Disease

Khasnur Abd Malek, Ilham Ameera Ismail

Department of Primary Care Medicine, Faculty of Medicine, Universiti Teknologi MARA (UiTM), Selangor, Malaysia.

Received

13th December 2019

Received in revised form

01st February 2020

Accepted

09th March 2020

Corresponding author:

Ilham Ameera Ismail,

Department of Primary Care Medicine,

Faculty of Medicine,

Universiti Teknologi MARA (UiTM),

Selayang Campus,

Jalan Prima Selayang 7,

68100, Batu Caves,

Selangor, Malaysia.

Email: drilham874@gmail.com

Tel: 603-6126 4600

Fax: 603-6126 4888

ABSTRACT

Hand, foot and mouth disease (HFMD) is an uncommon infection to be diagnosed in adults. We present a case of a 32-year-old immunocompetent man with HFMD. This case report highlights the importance of identifying a common childhood disease that could occur in an adult. Recognition is important for possible role in notification, especially for outbreak prevention and to consider potential differential diagnoses. The management and disease prevention measures in a working adult in Malaysia and the shortfalls identified in management guidelines are discussed.

KEYWORDS: HFMD, adult HFMD, hand lesion, foot lesion, rash

INTRODUCTION

HFMD is a contagious disease by human enteroviruses infection. The viruses involved include the Coxsackie group A and B, echoviruses and Enteroviruses 68 to 71. Its severity depends on the causative viruses involved. Coxsackie A16 infection is usually uneventful and results in spontaneous recovery. In contrast, HFMD caused by Enterovirus 71 (EV71) is more severe and is associated with complications [1,2].

Although HFMD is a common infection among the children, it can also occur in adults, particularly in those who are immunosuppressed. Among the immunocompetent adults, there has been no reported incidence rate in Malaysia and worldwide but cases have been reported [3,4]. The infection in immunocompetent adults are usually milder, with less typical presentation and some are totally asymptomatic. Concurrent lesions on the hands, feet, and in the oral

cavity can occur but are uncommon [3]. Therefore, although infected, adult patients may not come to seek treatment.

In immunocompetent adults, HFMD infection resulting in clinical manifestation has been reported to be caused by both the common HFMD strain such as Coxsackie A6 [4] and the uncommon strain such as Coxsackie A9 [5]. There have been reports on atypical clinical presentation in immunocompetent adults [4,6] and one given explanation was the potential change of the common Coxsackie A6 to a more virulent virus. [4,7]. Several factors have been strongly associated with the HFMD infection in immunocompetent adults including being male as compared to female, climate factor such as springtime and rainy season [3], and during an outbreak [4].

HFMD spread via respiratory droplets, bodily fluids and feces. Its incubation period is short, between

three to six days. The initial disease manifest with low-grade fever, cough, and sore throat. General malaise and appetite loss can be present. Following the initial symptoms, the erythematous vesiculopapular rash starts to progress to involve the mouth, limbs and trunk. While most clinical signs are mild, some may develop complications such as encephalitis and myocarditis [1-3]. When only oral lesion is present, other differential diagnoses such as herpes simplex infection, aphthous stomatitis, herpangina, erythema multiforme and adverse drug reaction should be considered [8]. HFMD can be a clinical diagnosis but viral isolation through the highly sensitive and specific polymerase chain reaction (PCR) confirms the diagnosis [1,2]. The case report highlights an important notifiable childhood disease that could occur uncommonly in an adult.

CASE PRESENTATION

A 32-year-old man presented at day four of illness at a university primary care clinic with tender rash at palms and soles for two days. This was preceded by two-days history of fever which resolved spontaneously just before the rash appeared. There was no involvement to the other part of the body. Patient complained of sore throat as well as general joint and body aches which had resolved upon coming to the clinic. He had no significant past medical history and did not take any medication or supplements. His 11-month-old daughter who stays with him was clinically diagnosed with hand, foot and mouth disease (HFMD) one week prior to his presentation. His daughter was taken care of by a paid babysitter. He had no history of sexual promiscuity. His wife and the babysitter were well.

The patient also had history of going to a private general practice clinic at day three of illness. Full blood count was done at the clinic. His haemoglobin level was 14.1 g/dl (normal range 13.0-17.0), total white count $7.3 \times 10^3/\mu\text{L}$ (normal range 4.0-10.0) and platelet count was $254 \times 10^3/\mu\text{L}$ (normal range 250-410). He was informed to go to the hospital for further investigation of possible vasculitis but the patient came the university primary care clinic for second opinion.

Clinical examination revealed multiple erythematous papules and vesicular rash over the palms, fingers, soles and dorsum of the feet (Figure 1 and Figure 2). These were tender when pressure was applied. The mouth and other areas of the body were spared. His tonsils were inflamed without exudates. He had no joint swelling. He was afebrile and looked well. His cardiovascular was normal with absence of pericardial rub and his other system examinations were normal.

A clinical diagnosis of HFMD was made in this patient with recent diagnosis of HFMD in his daughter prior to him manifesting the cutaneous rash. His clinical disease presentation and disease progress supported the diagnosis of HFMD.

He was treated symptomatically with NSAIDs on as needed basis (of which the patient informed upon follow up a week later that it was not needed) and medical certificate (MC) was given. Advice on good personal hygiene and limiting direct close contact were given. Within a week, the vesicular-papular rash on the hands resolved fully. The lesions on the feet became dry, white and peeled off within 2-3 weeks.

Figure 1 Lesions on the hand

- a: The rash on the right thumb
- b: The rash on the right palm

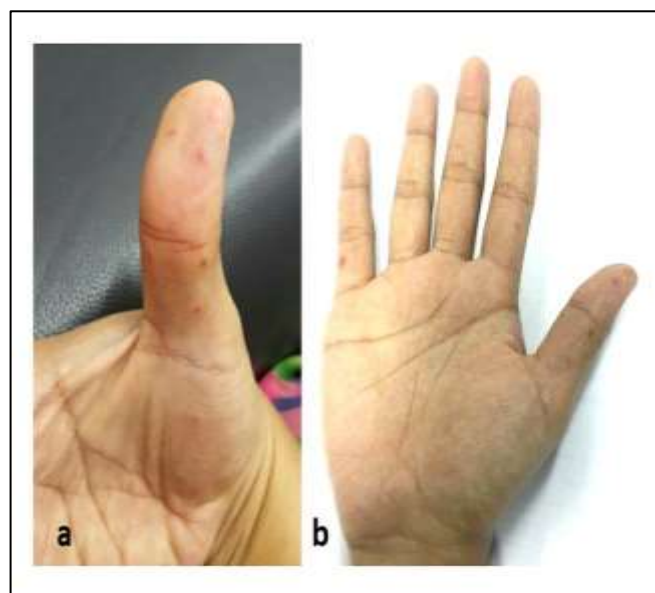
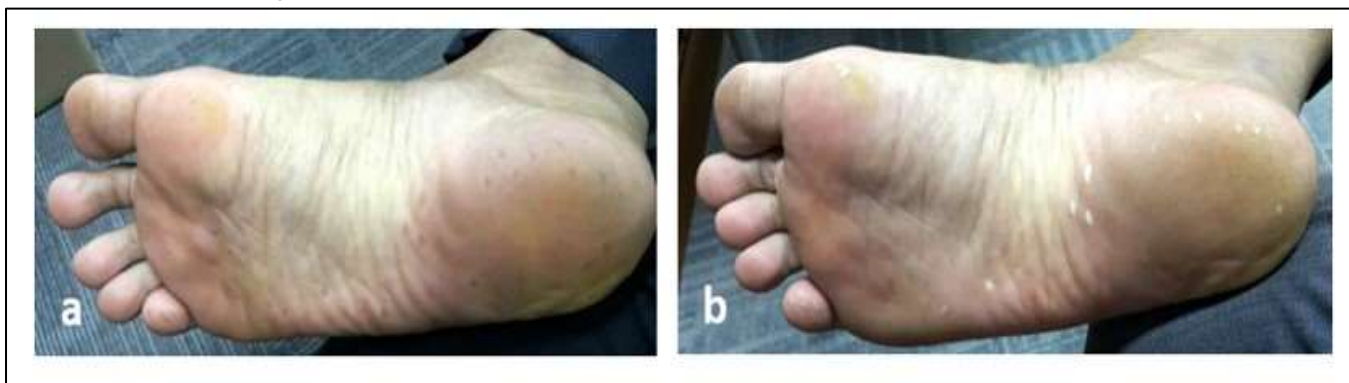

Figure 2 Lesions on the foot**a:** The rash on the right foot at presentation**b:** The rash on the right foot at 2 weeks

DISCUSSION

This case is an example of a relatively rare HFMD infection in an immunocompetent adult, which required symptomatic treatment as per needed basis. Blood investigations for general health are not usually needed for uncomplicated HFMD cases and recovery is usually observed within seven to ten days [8]. Further investigations need to be considered in cases with prolonged clinical symptoms or when oral lesions are the only presentation, to look for differential diagnoses. Management of uncomplicated cases of HFMD is generally supportive such as analgesia and treating mouth ulcers. Patients must be counselled to look out for warning signs that point to the development of complications. In severe disease, intravenous immunoglobulin may be required [2].

Prevention of disease spread is essential. HFMD can be contained by practicing good personal hygiene and avoidance of direct contact to other individuals [2,3]. Infected adults either symptomatic or not, are contagious during the first week of the illness through direct contact via skin and mucosal lesions. For adults with active infection and work in close contact with children or elderly population, recommendation for isolation is beneficial. Enteroviruses can continue to be excreted in the stool for up to six weeks but its clinical significance is uncertain [2].

In Malaysia, notifying of infectious diseases is mandated by the Prevention and Control of Infectious Disease Act 1988. The Prevention and Control of Infectious Diseases (Notice Form) regulations was

gazetted in 1993, and to date, a total of 28 infectious diseases conditions are required to be notified by law [10]. HFMD is a notifiable disease since 2006 [1]. All suspected and confirmed cases need to be notified to the nearest District Health Office within 24 hours of diagnosis. However, the 2017 clinical case definition for HFMD by the Ministry of Health Malaysia is any child aged 10 year-old and below, with mouth or tongue ulcer and maculopapular rashes and/or vesicles on palms and soles, with or without history of fever [9].

From public health point of view, HFMD, even when it occurs in adults, should also be notifiable. The age of 10 years old in the clinical case definition limits the notification for adults. Adults can also be involved as a source of spread of disease. Notification is essential to contain and monitor an outbreak especially if it is caused by the virulent EV71. Even though the case did not fulfill the clinical case definition as it occurred in an adult, the treating doctor felt that it is an important infectious disease, especially when it occurred within one week of his daughter's diagnosis. It was notified to the local authorities as a suspected case. The Malaysia guideline states that an outbreak is the occurrence of two or more cases in the same locality within the incubation period (6 days) and recommends a mouth swab, blister swab or stool for confirmation in suspected cases [1,9]. However, currently, confirmation is done only in a large outbreak. Samples from 10% of the cases (but not more than 5 samples for each outbreak) that meet the clinical criteria of HFMD will be sent for laboratory testing if no laboratory confirmation of the

causative agent was already done within the same locality [9].

There is currently no specific local guideline on the recommendation for isolation or medical leave for adults with HFMD. In this case, the patient is a librarian that has contact with the public and would need a prolonged medical leave. There is no specified quarantine leave that could be given for Government employees in Malaysia with HFMD but based on the clinical findings, medical leave can be given at the doctor's discretion.

A parent with a child who was diagnosed with HFMD on the other hand can apply for an allocated quarantine leave to take care of their sick child as the child is not allowed to attend nursery or school for at least 10 days from the onset of illness [1,10] At the moment, there is no approved vaccination towards HFMD but several are under development, such as the EV71 vaccine [2,3].

In conclusion, it is important for primary care doctors to recognize common childhood illnesses manifesting in adults and how disease presentation and progression can differ. Notifiable diseases should be recognized, managed and notified early at the primary care level to prevent an outbreak. Containment of HFMD can be achieved with simple personal hygiene measures and isolation advice where appropriate. Adults can also be involved as patients in outbreaks and surveillance or notification system as well as practice guidelines should include specific recommendations on the management of adults with HFMD.

Conflict of Interest

Authors declare none

Acknowledgement

We would like to acknowledge Dr Rafidah Mahmud and Dr Ernie Rozaini for their role in the management of the patient. Permission to report the case from the patient was obtained.

Author's Contribution

KA Malek and IA Ismail are the Family Medicine Specialists involved in the management of the case and the writing of the case report.

REFERENCES

1. Disease Control Division, Ministry of Health Malaysia. Hand Foot and Mouth Disease Guideline. 2007.
2. World Health Organization Western Pacific Region. A Guide to clinical management and public health response for hand, foot and mouth disease (HFMD). Geneva: World Health Organization. 2011.
3. Omaña-Cepeda C, Martínez-Valverde A, del Mar Sabater- Recolons M, Jané-Salas E, Marí-Roig A, López-López J. A literature review and case report of hand, foot and mouth disease in an immunocompetent adult. *BMC Res Notes*. 2016;9:165. doi:10.1186/s13104-016-1973-y..
4. Kaminska K, Martinetti G, Lucchini R, Kaya G, Mainetti C. Coxsackievirus A6 and Hand, Foot and Mouth Disease: Three Case Reports of Familial Child-to-Immunocompetent Adult Transmission and a Literature Review. *Case Rep Dermatol*. 2013;5(2):203-209.
5. Bárbara Flor de Lima, João Silva, Ana Catarina Rodrigues, Ana Grilo, Nuno Riso & Manuel Vaz Riscado. Hand, foot, and mouth syndrome in an immunocompetent adult: a case report *BMC Res Notes*. 2013;6: 441. doi: 10.1186/1756-0500-6-441.
6. Stewart CL, Chu EY, Introcaso CE, Schaffer A, James WD. Coxsackievirus A6–Induced Hand-Foot-Mouth Disease. *JAMA Dermatol*. 2013;149(12):1419-1421.
7. Rajni Sharma, Sujaya Manvi. Hand, Foot and Mouth Disease Case Reports of Familial Child to Immunocompetent Adult Transmission. *J Med Sci Clin Res*. 2018; 6(1):32085-32089.
8. Wolff K, Johnson RC, Saavedra A, Roh EK. Viral Diseases of Skin and Mucosa. In: Fitzpatrick's Color Atlas and Synopsis of Clinical Dermatology. 8th ed. McGraw-Hill, NY. 2013. pp. 671.
9. Disease Control Division, Ministry of Health Malaysia. Case Definitions for Infectious Diseases in Malaysia. 3rd Edition. 2017. pp. 31-32.
10. Kerajaan Malaysia, Pekeliling Perkhidmatan Bilangan 11 Tahun 2016: Kemudahan Cuti Kuarantin. JPA.Saraan 223/5/4-3 JLD.3 (13) [Government of Malaysia, Service Circular No. 11 Year 2016: Quarantine Leave Facilities. JPA.Remuneration 223/5/4-3 JLD.3 (13)]