

### COMMANDO in Locoregional Recurrence of Oropharyngeal Carcinoma

Abdul Azim Al-Abrar Ahmad Kailani<sup>1,2</sup>, Ahmad Kusyairi Khalid<sup>3</sup>, Mohd Razif Mohamad Yunus<sup>4</sup>, Irfan Mohamad<sup>1</sup>

<sup>1</sup>Department of Otorhinolaryngology-Head and Neck Surgery, School of Medical Sciences, Universiti Sains Malaysia (USM), Kelantan, Malaysia

<sup>2</sup>Department of Otorhinolaryngology-Head and Neck Surgery, Faculty of Medicine, Universiti Teknologi Mara (UiTM), Selangor, Malaysia

<sup>3</sup>Universiti Teknologi Mara (UiTM) Private Specialist Centre, Selangor, Malaysia

<sup>4</sup>Department of Otorhinolaryngology-Head and Neck Surgery, Faculty of Medicine, Universiti Kebangsaan Malaysia (UKM), K. Lumpur, Malaysia

#### Received

23<sup>rd</sup> February 2020

#### Received in revised form

04<sup>th</sup> May 2020

#### Accepted

15<sup>th</sup> May 2020

#### Corresponding author:

**Irfan Mohamad,**

Department of Otorhinolaryngology-

Head and Neck Surgery,

School of Medical Sciences,

Universiti Sains Malaysia Health

Campus,

16150 Kota Bharu

Kelantan, Malaysia.

Email: irfankb@usm.my

#### ABSTRACT

Squamous cell carcinoma is the most common malignant neoplasm of the upper aerodigestive tract, and presentation is usually at the late stages when the diagnosis is made. Recurrence after 1st therapy is common especially in the locoregional area of the tumour. For cancers affecting the oral cavity, oropharynx, and mandible, "COMMANDO" (Combined Mandibulectomy and Neck Dissection Operation) is one of the surgical approaches which constitutes of primary tumour resection, mandibulectomy and neck dissection. We describe a case of rapid locoregional recurrence following 1st surgical procedure of bilateral tonsillectomy and extended neck dissection of oropharyngeal squamous cell carcinoma in a young healthy individual without history of alcohol and tobacco abuse involving the right buccal region which after positron emission tomography was done, showed involvement of right pterygoid muscles, right-sided tongue muscle, and right mandible. The patient underwent redo salvage surgery and reconstruction with anterolateral thigh flap.

**KEYWORDS:** Oropharynx carcinoma, recurrence, COMMANDO (Combined Mandibulectomy and Neck Dissection Operation), Human papillomavirus, Salvage surgery

#### INTRODUCTION

Squamous cell carcinoma (SCC) may develop from any anatomical subsites in the head and neck region. Chronic tobacco and alcohol consumption together with infection of oncogenic viruses are among well-established risk factors for the development of oropharyngeal squamous cell carcinoma (OPSCC). Head and neck SCC are previously known as a disease of the middle age with a strong association with tobacco and alcohol usage due to its synergistic effect. For the past 10 years, the prevalence of human papillomavirus (HPV) associated OPSCC is increasing worldwide.

Generally, surgery or radiotherapy (RT) is the treatment of choice for early-stage squamous cell cancers of the head and neck. In comparison, with locally advanced head and neck cancers where surgery followed by adjuvant RT or chemoradiation are opted [1]. Another major predictor is HPV tumour status where both HPV-positive OPSCC and HPV-negative

OPSCC have the same management protocol but HPV positivity has better prognosis when treated with chemoradiotherapy.

For operable OPSCC, COMMANDO (Combined Mandibulectomy and Neck Dissection Operation) is one of the approaches constituting primary tumour resection, removing a part of the mandible and neck dissection of the affected cervical lymph nodes. The amount of mandible removed is according to the size and location of the lesion. Tracheostomy is also regularly performed prior. Reconstruction is needed to cover the large mucosal defect with free skin graft and plating of the remaining mandible to preserve the function. For recurrent operable disease, salvage surgery is indicated after curative chemoradiotherapy but depends greatly on location, the extension of the disease, and previous treatment [2].



## CASE PRESENTATION

A 43-year-old Indonesian Chinese male presented with a mass at the right tonsil region for 5 months associated with dysphagia, odynophagia, loss of appetite, and loss of weight. The mass was gradually increasing in size. He is a non-smoker, non-alcoholic, no history of betel nut chewing, and denies risky sexual behaviour. There was also a 1 cm x 1 cm node palpable at right level II and biopsy taken from the right tonsil region and was proven to be SCC. Initial staging was T2N1M0. He underwent bilateral tonsillectomy and bilateral extended neck dissection and later completed chemotherapy and RT 2 months after surgery due to positive surgical margins.

However, 4 months after chemoradiotherapy he developed right buccal mass which was painful, increasing in size and associated with severe trismus. On physical examination, there was a mass at the right cheek measuring 6 cm x 5 cm, which was firm and tender (Figure 1). The mass was fixed to the underlying structures but there was no overlying skin change. The intraoral examination was very limited due to severe trismus. There was a 2 cm x 1 cm node palpable at right level I with a well-healed apron incision from previous neck dissection. Rigid endoscopy showed ulcerative lesion around the right tonsil region with an intact larynx and airway. Other ENT examination was unremarkable.

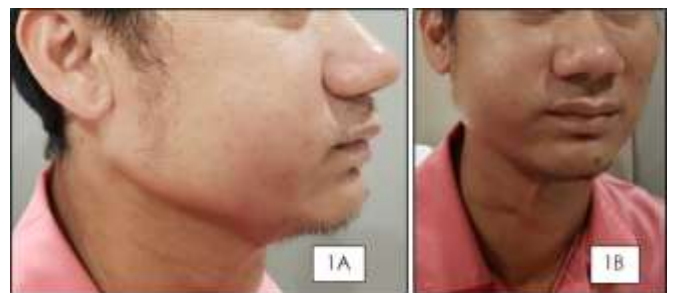Magnetic resonance imaging (MRI) of the base of skull and neck revealed heterogeneous enhancing mass in inferolateral part of right tonsillar bed measuring 1.5 cm in thickness with the involvement of right medial and lateral pterygoid muscles, right masseter, right buccinator, right mylohyoid and hyoglossus muscle with bone marrow changes of the right mandible from the neck, angle, and body (Figure 2).

He was further investigated with positron emission tomography (PET) for restaging and precise delineation of the tumour within the right mandible and cervical lymph node involvement. PET-CT showed fluorodeoxyglucose (FDG)-avid medial to the right mandible and extending to the lateral and anterior part of the mandible with tooth involvement. However, there was no evidence of FDG-avid metastatic lymph nodes.

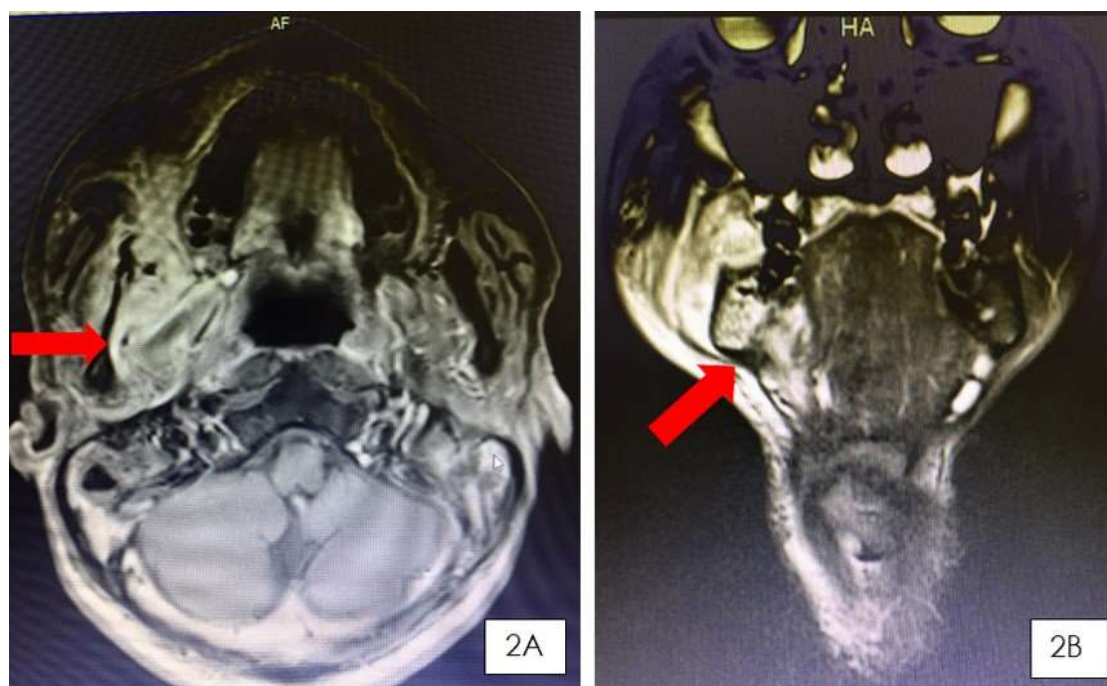
The clinical and radiological staging of this patient was rT4N1M0 and second salvage surgery was opted due to previous chemo and RT and taking into consideration the patient's age and no comorbidities. He underwent tracheostomy under local anesthesia, excision of the tumour, right hemimandibulectomy, right inferior maxillectomy, revision of bilateral neck dissection, free fibular flap reconstruction by the plastic team and percutaneous endoscopic gastrostomy tube insertion for feeding. Tumour debulking and clearance were done till the base of skull macroscopically.

The histopathological examination (HPE) showed fibrocollagenous tissue with the presence of skeletal muscle bundles infiltrated by cords and tongues of moderately to poorly-differentiated malignant squamous cells. The malignant cells have enlarged vesicular-to-hyperchromatic nuclei, showed the presence of multinucleation and bizarre cells with frequent mitosis. There were perineural invasion and invasion into the skeletal muscle layer. Interestingly, the right level I node was foreign body granulomas, and no malignancy seen. Unfortunately, no HPV staining was done in our case.

During our follow-up one month after surgery, his wound was healing well and the flap was viable with better mouth opening to 2 and a half fingerbreadths. There were no signs of recurrence clinically and repeated PET scan after 1 month showed no evidence of FDG avid uptake in the oropharynx and distant organs. Furthermore, he was planned for PET-CT surveillance and feeding through a PEG tube until the wound completely healed and was referred to a speech therapist for chewing, swallowing, and speech rehabilitation.



**Figure 1:** Mass at the right cheek from lateral (A) and anterior view (B).



**Figure 2:** Heterogeneous enhancing mass in the right tonsillar bed in axial view (A) with involvement of the right mandible in coronal view (B).

## DISCUSSION

The locoregional recurrence rate after salvage surgery for OPSCC ranges from 50% to 60%. In our case, recurrence occurs after the patient underwent both surgery and chemoradiation thus second salvage surgery was the only option as the tumour was still resectable. In other words, the prevertebral fascia and cavernous sinus were not involved and there was no encasement of the carotid artery. Re-irradiation was not an option in our case considering the patient had been irradiated in less than one year since completion of the definitive full dose of RT. The overall survival is only a few months with re-irradiation and related to high morbidity and mortality of 33% and 10% respectively [3].

Local recurrence is diagnosed when a tumour arising from residual microscopic foci of tumour cells in the previously operated site [4]. A tumour recurrence can also be classified if there is a tumour-free period for 3 months or more after the initial treatment [5]. The prognosis is better if recurrence develops after 6 months compared to earlier recurrence in which palliative treatment is suggested. Another prognostic indicator is surgical margins where better prognosis can be achieved with free margins compared to positive or close margins histopathologically. This is evidenced by

3-year cancer-specific survival of 25.8% and 9.3% respectively for free and positive margins. Thus, careful surgical planning aiming for free surgical margins is of utmost importance [6]. Our patient had recurrence within 4 months. The decision for second salvage was made because the patient has no underlying comorbidities, good social support, and eager to undergo the salvage treatment.

Second salvage surgery is only for highly selective patients and based on individual patient. The criteria that must be fulfilled by the candidates are good performance status, no comorbidities, willingness for a surgical salvage attempt, and good social support. This is explained by the considerable negative impact of the major surgery on functional and performance status [7,8].

Younger, healthier non-smoking men with multiple sexual partners are a typical history of HPV-positive OPSCC patients [9]. HPV-positive OPSCC originates with exposure to high-risk HPV, a sexually-transmitted virus especially HPV type 16, and can develop even without alcohol or tobacco exposure [10]. The tumour histology of HPV related OPSCC is usually basaloid, lymphoepithelial, or poorly differentiated [11]. HPV is also strongly associated with tonsillar cancer. Steinberg and DiLorenzo [12] reported HPV



infection is detected in tonsil, larynx, tongue, and the floor of the mouth, in descending order. Tonsillar cancers with positive HPV are common in young, non-smokers, and non-drinkers.

Regardless of the HPV status, OPSCC currently is managed according to the same treatment protocols. Early-stage T1-T2 N0-N1 OPSCC can be treated with either surgery or RT. Disease-specific 5-year survival between surgical versus non-surgical management of early-stage OPSCC was 69% and 60% respectively and statistically no significant difference [13]. RT is usually delivered at a total dose equivalent of 70 Gy in 35 fractions. For more advanced stage III/IV OPSCC, primary chemoradiotherapy is the standard of care, or surgery and adjuvant chemoradiotherapy. The concurrent cisplatin is given at a dose of 100 mg/m<sup>2</sup>, on days 1, 22, and 43 of the RT schedules.

The overall median survival following salvage surgery was 53.8 months for OPSCC. Overall survival rates were 98%, 77.2%, and 43.7% for 1-, 2-, and 5-year respectively. One-fifth of the relapse rate occurs at a median time of 8 months with most of the recurrences occurring within 2 years [14]. Complications are more common in OPSCC and requiring more secondary procedures. The majority of patients need an entero-gastric feeding tube and few patients returned to a normal diet [15].

Surgical salvage improves overall survival regardless of their HPV status in locoregional recurrence and even with distant metastases. The HPV-positive tumour has a longer disease-free interval but interestingly not directly associated with a significant reduction in the risk of death. Patients with recurrent OPSCC must be counselled regarding the potential survival advantages of surgical salvage, regardless of HPV tumour status or site of disease recurrence either locoregional or distant [16]. HPV vaccine may play a role in preventing HPV 16 oropharyngeal infection and subsequent OPSCC development but there is no study that has been conducted to evaluate the effect of the vaccine either on the oropharyngeal infection or carcinoma development for now.

## CONCLUSION

Recurrent SCC of the oropharynx remains a challenging entity to manage in head and neck cancer with unfavourable outcomes. Second salvage surgery with COMMANDO (Combined Mandibulectomy and Neck Dissection Operation) is a potentially curative approach for a highly selected group of patients who have previously undergone salvage surgery. Despite HPV status, salvage treatment should be considered in patients with a resectable disease and good performance status to achieve better overall survival.

## Conflict of Interest

Authors declare none.

## REFERENCES

1. Marur S, Forastiere AA. Head and Neck Squamous Cell Carcinoma: Update on Epidemiology, Diagnosis, and Treatment. *Mayo Clin Proc.* 2016;91(3):386-96. doi: 10.1016/j.mayocp.2015.12.017.
2. Zafereo M. Surgical Salvage of Recurrent Cancer of the Head and Neck. *Curr Oncol Rep.* 2014;16(5):386.
3. Strojan P, Corry J, Eisbruch A, Vermorken JB, Mendenhall WM, Lee AW, Haigentz M Jr, Beitler JJ, de Bree R, Takes RP, Paleri V, Kelly CG, Genden EM, Bradford CR, Harrison LB, Rinaldo A, Ferlito A. Recurrent and Second Primary Squamous Cell Carcinoma of the Head and Neck: When and How to Reirradiate. *Head Neck.* 2015;37(1):134-50.
4. Woolgar JA, Rogers S, West CR, Errington RD, Brown JS, Vaughan ED. Survival and Patterns of Recurrence in 200 Oral Cancer Patients Treated by Radical Surgery and Neck Dissection. *Oral Oncol.* 1999;35(3):257-65.
5. Lacy PD, Spitznagel Jr EL, Piccirillo JF. Development of A New Staging System for Recurrent Oral Cavity and Oropharyngeal Squamous Cell Carcinoma. *Cancer.* 1999;86(8):1387-95.
6. Agra IM, Filho JG, Martins EP, Kowalski LP. Second Salvage Surgery for Re - recurrent Oral Cavity and Oropharynx Carcinoma. *Head Neck.* 2010;32(8):997-1002. doi: 10.1002/hed.21298.

7. Piccirillo JF, Vlahiotis A. Comorbidity in Patients with Cancer of the Head and Neck: Prevalence and Impact on Treatment and Prognosis. *Curr Oncol Rep.* 2006;8(2):123-9. doi: 10.1007/s11912-006-0047-z.
8. Hall SF, Groome PA, Irish , O'Sullivan B. Towards Further Understanding of Prognostic Factors for Head and Neck Cancer Patients: The Example of Hypopharyngeal Cancer. *Laryngoscope.* 2009 ;119(4):696-702. doi: 10.1002/lary.20112.
9. Smith EM, Ritchie JM, Summersgill KF, Klusmann JP, Lee JH, Wang D, Haugen TH, Turek LP. Age, Sexual Behavior and Human Papillomavirus Infection in Oral Cavity and Oropharyngeal Cancers. *Int J Cancer.* 2004;108(5):766-72.
10. Gillison ML, Koch WM, Capone RB, Spafford M, Westra WH, Wu L, Zahurak ML, Daniel RW, Viglione M, Symer DE, Shah KV, Sidransky D. Evidence for A Causal Association Between Human Papillomavirus and A Subset of Head and Neck Cancers. *J Natl Cancer Inst.* 2000;92(9):709-20.
11. Marur S, Forastiere AA. Head and Neck Cancer: Changing Epidemiology, Diagnosis, and Treatment. *Mayo Clin Proc.* 2008;83(4):489-501.
12. Steinberg BM, DiLorenzo TP. A Possible Role for Human Papillomaviruses in Head and Neck Cancer. *Cancer Metastasis Rev.* 1996;15(1):91-112.
13. Garden AS, Morrison WH, Wong PF, Tung SS, Rosenthal DI, Dong L, Mason B, Perkins GH, Ang KK. Disease-control Rates Following Intensity-Modulated Radiation Therapy for Small Primary Oropharyngeal Carcinoma. *Int J Radiat Oncol Biol Phys.* 2007;67(2):438-44.
14. Kissun D, Magennis P, Lowe D, Brown JS, Vaughan ED, Rogers SN.. Timing and Presentation of Recurrent Oral and Oropharyngeal Squamous Cell Carcinoma and Awareness in the Outpatient Clinic. *Br J Oral Maxillofac Surg.* 2006;44(5):371-6.
15. Kostrzewa JP, Lancaster WP, Iseli TA, Desmond RA, Carroll WR, Rosenthal EL. Outcomes of Salvage Surgery with Free Flap Reconstruction for Recurrent Oral and Oropharyngeal Cancer. *Laryngoscope.* 2010;120(2):267-72.
16. Guo T, Qualliotine JR, Ha PK, Califano JA, Kim Y, Saunders JR, Blanco RG, D'Souza G, Zhang Z, Chung CH, Kiess A, Gourin CG, Koch W, Richmon JD, Agrawal N, Eisele DW, Fakhry C. Surgical Salvage Improves Overall Survival for Patients with HPV-positive and HPV-negative Recurrent Locoregional and Distant Metastatic Oropharyngeal Cancer. *Cancer.* 2015;121(12):1977-84.