

### Parotid Gland Tumour Presenting in Primary Care: The Importance of Histological Confirmation

Aiza Nur Izdihar Zainal-Abidin<sup>1</sup>, Farnaza Ariffin<sup>1</sup>, Siti Fatimah Badlishah-Sham<sup>1</sup>, Khariah Mat Nor<sup>2</sup>, Geok Chin Tan<sup>3</sup>

1 Department of Primary Care Medicine, Faculty of Medicine, Universiti Teknologi MARA, Selayang Campus, Selangor, Malaysia

2 Department of Radiology, Faculty of Medicine, Universiti Teknologi MARA, Sungai Buloh Campus, Selangor, Malaysia

3 Department of Pathology, Faculty of Medicine, Universiti Kebangsaan Malaysia, Kuala Lumpur, Malaysia

#### Received

27<sup>th</sup> November 2020

#### Received in revised form

31<sup>st</sup> January 2021

#### Accepted

20<sup>th</sup> February 2021

#### Corresponding author:

**Assoc. Prof. Dr Farnaza Ariffin**,  
Department of Primary Care Medicine,  
Faculty of Medicine,  
Universiti Teknologi MARA,  
Selayang Campus, Jalan Prima  
Selayang 7, 68100 Batu Caves,  
Selangor, Malaysia.  
Email: farnaza@uitm.edu.my  
Tel. no: 016-7761654  
Fax no: 03-61268888

#### ABSTRACT

This is a report of a patient presenting to a primary care clinic with slow growing parotid gland swelling which was initially suspected as benign from ultrasound findings. A referral to the ORL (otorhinolaryngology) team was made and FNAC (Fine Needle Aspiration Cytology) results confirmed the swelling to be Acinic Cell Carcinoma. The patient subsequently underwent surgical resection. This case highlights the importance of a high clinical suspicion of malignancy in those presenting with slow growing salivary gland tumours due to its indolent nature and imaging difficulties. Histological confirmation is warranted.

**KEYWORDS:** Primary Care, Parotid swelling, Acinic Cell Carcinoma

#### INTRODUCTION

Neck swellings are a common presentation in primary care. A diagnosis of a swelling can be made via careful history taking, thorough physical examination and aided by imaging tools [1]. The goal is to determine the cause and whether the swelling is malignant or benign. The characteristic and duration of the swelling is important in determining the cause. An acute and symptomatic growth is commonly caused by infection which abates after symptoms resolve. If a neck swelling does not resolve within four to six weeks, a biopsy is warranted especially if there is an association with constitutional symptoms [1, 2]. A persistent (chronic) unexplained swelling in the neck is considered malignant until proven otherwise and should be promptly investigated [1, 2].

#### CASE PRESENTATION

A 33-year-old man presented to a primary care clinic with right sided neck swelling which has been slowly increasing in size over the past one year. This was the first time he sought medical attention for the swelling. It was initially painless, but recently he found that the swelling was painful to touch but no pain during eating. There is no history of fever, upper respiratory tract, dental or ear, nose and throat symptoms. He denied symptoms of hypo or hyperthyroidism and had no obstructive or constitutional symptoms. He has no previous medical illness and no history of allergy. He ceased smoking 3 years ago and does not engage in high-risk sexual behaviour.

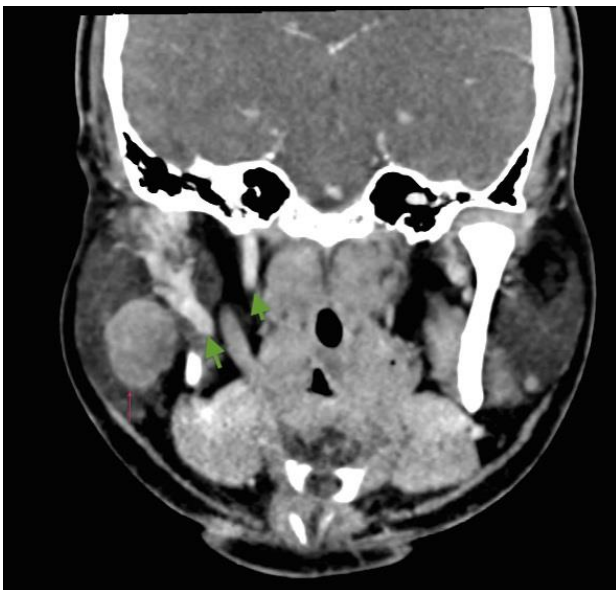


His vital signs were normal. On examination, there was a 3 cm x 3 cm swelling at the right mandible angle, in the parotid gland topography with normal overlying skin. On palpation, the swelling was mildly tender, firm in consistency, mobile, smooth, non-fluctuant and not warm to touch. The cervical lymph nodes were not enlarged. The oral cavity revealed a normal Stenson's duct opening. The seventh cranial nerve was intact. The rest of the physical examination was unremarkable. The impression at the time was of a right parotid swelling.

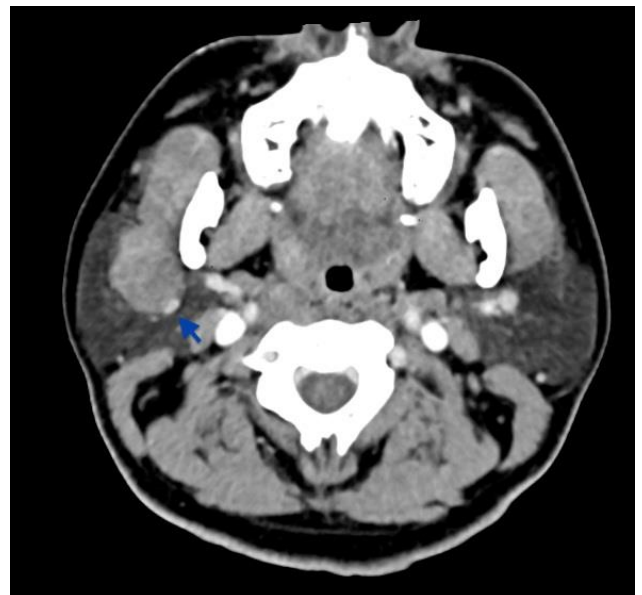
Biochemical investigations including a full blood count, renal profile, liver function test, ESR and random sugar were within normal ranges. From the point of the first presentation, ultrasound was scheduled two weeks later before patient was subsequently referred to ORL who saw him three months afterward.

Ultrasonography of the swelling reported a well-defined lobulated hypoechoic mass within the postero-inferior aspect of the right parotid gland measuring 2.0(AP) x 2.4(Wt) x 2.8(Ht)cm. There was no internal calcifications or increased vascularity. The rest of the right parotid gland is homogeneous in echogenicity and echotexture. It was reported that the swelling was most likely a pleomorphic adenoma.

Due to the suspected benign nature of the swelling supported by the ultrasound report, the patient was referred routinely to the ORL team for FNAC. The patient was seen in the ORL outpatient three months later and FNAC was performed two weeks after ORL surgeon's first review. FNAC of the parotid swelling was performed using a syringe holder with a 23-gauge needle. Cytological examination showed clusters of large polygonal cells demonstrating abundant vacuolated cytoplasm which are features consistent with Acinic cell carcinoma (ACC).



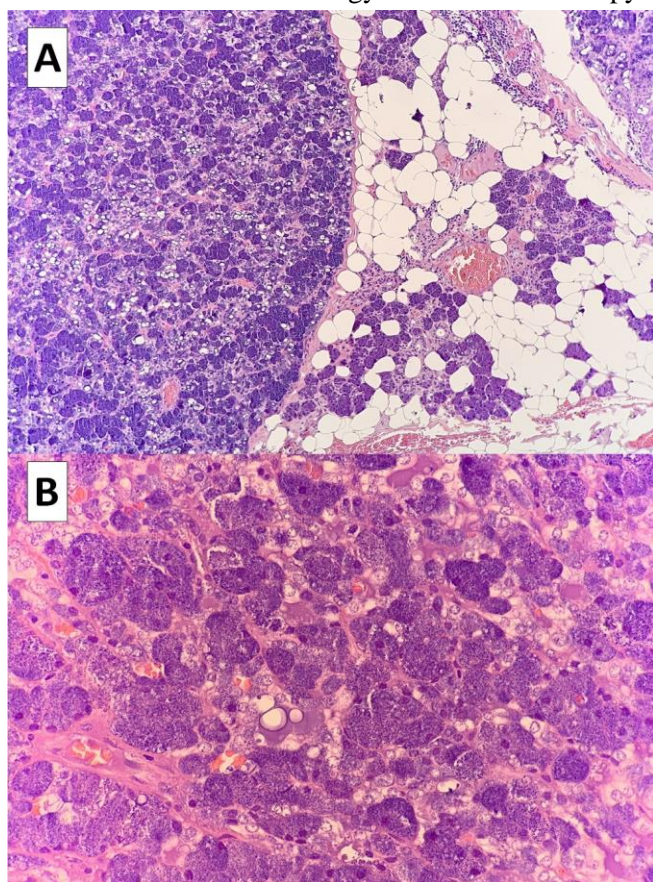
**Figure 1A** Contrast enhanced computed tomography of the neck from the axial plane



**Figure 1B** Contrast enhanced computed tomography of the neck from the coronal plane

**Figure 1 (1A & 1B).** A contrast enhanced computed tomography of the neck; coronal and axial planes show a well-defined lobulated mass (red arrow) within the superficial part of the right parotid gland measuring 2.9(AP) x 2.4(Wt) x 3.0(Ht)cm. It shows homogenous enhancement, and abuts the posterior surface of the right masseter muscle. It compresses onto the right retromandibular vein (blue arrow), however, normal opacification of this vein is observed. No areas of necrosis or foci of calcifications. Bilateral sub-centimeter cervical, submandibular and submental lymph nodes are present. The green arrows indicate normal enhancement of the neck vessels, namely IJV (Internal Jugular Vein) and CCA (Common Carotid Artery).

Following a cytological diagnosis of ACC, the patient was advised to undergo excision. A preoperative CT scan of the neck, thorax, abdomen and pelvis confirmed the extent of the carcinoma and showed no evidence of distant metastasis. The contrast enhanced CT neck of the patient is shown in Figure 1. The treatment of choice is complete surgical excision and the patient underwent a total parotidectomy with facial nerve preservation. Histopathological report revealed Acinic cell carcinoma from the deep lobe of excised right parotid, WHO grade pT3 N0 (T3- Tumour larger than 4 cm and/or tumour having extra-parenchymal extension. N0- No regional lymph node metastasis (Prognostic stage group: III)) The tumour size was 4.5cm x 2.0cm x 1.5cm and the surgical margins were not involved. The tumour is composed of sheets of neoplastic cells displaying small nuclei and abundant cytoplasm with basophilic granules as shown in Figure 2. No tumour was found from the superficial lobe specimen. Following a successful removal of the ACC, he was referred to the oncology team for radiotherapy.



**Figure 2** Histopathology of the tumour from the complete surgical excision. The tumour is composed of sheets of neoplastic cells with abundant basophilic granules (A-H&E stain, X10; B-H&E, X40).

## DISCUSSION

Salivary gland tumours are relatively rare and accounts for only 3-5% of all head and neck malignancies [3]. Acinic cell carcinoma (ACC) is a low-grade slow growing malignant tumour. It is the rarest type of salivary gland tumour, as the prevalence is only 1% to 17% of all primary salivary gland malignancies worldwide [3, 4]. To date, there is no local data on incidence of salivary gland malignancies, specifically parotid gland ACC in the Malaysian National Cancer Registry Report 2007-2011. The lack of knowledge and exposure to salivary gland tumours may lead to misdiagnosis or delay in further investigation and treatment.

ACC occurs predominantly in the parotid gland, such as in this patient [5]. A systematic review of gender distribution varies between men and women depending on the country of origin, however, there is a tendency for female predominance [3]. The mean age for salivary gland tumours ranges from 41.9 to 43 years. For younger patients aged  $35.0 \pm 17.2$  years, the majority of them have benign tumours, meanwhile malignant tumours tend to affect the older patients aged  $48.8 \pm 18.2$  years old [3]. Our patient is a young male and therefore the suspicion of a malignancy may not have been high at the initial consultation.

This case also highlighted the challenges in identifying ACC that led to the delay in diagnosis. The challenge of early detection is due to its rarity and indolent behaviour as well as difficulties in ultrasound imaging to confirm malignancy. ACC was initially thought to be a benign growth due to its slow growing nature until it was conceived as malignant in 1953 [6]. It has been confirmed as true adenocarcinomas in the International Classification of Disease. Even though it is low grade and the least aggressive, WHO recognizes its potential to be aggressive. There are reported cases of local recurrences and distant metastasis [6, 7]. The aetiology of this malignancy is unknown but might be related to genetics or environmental-such as previous radiation exposure [5]. This patient has no known risk factors.

Ultrasound imaging can be done as widely available preliminary assessment for superficial lesions such as the parotid, submandibular and sublingual



glands to assess tumour size, location and tissue characterization without invasive or radiation hazard. It is best combined with FNAC [5, 8]. However, it alone is not the best modality in differentiating benign and malignant salivary gland tumours [8]. This case highlights this particular point because the initial ultrasound finding was reported as a pleomorphic adenoma which is a benign tumour. This is because pleomorphic adenoma and ACC have similar radiological features, thus, making it difficult to differentiate between the two disorders [5, 8]. There are no specific features of ACC found on ultrasound, CT or MRI apart from a common finding of a well-defined solid, cystic mass [5]. However, further imaging with either a CT or MRI is useful to evaluate the extent of the mass especially for lesions of the deep lobe and to provide pre-operative details of the tumour [1, 8].

Ultrasound guided FNAC is routinely recommended as the tumours may have overlapping features. It is a rapid, safe and helpful procedure that provides definitive diagnosis to further counsel patients on the need of surgery [8]. Thus, the recommended flow for diagnostic workout for a parotid gland swelling is an ultrasound guided FNAC or biopsy. It was following the FNAC results that ACC was diagnosed and thus led to further surgical management of the parotid tumour. Even though ACC is a slow-growing tumour, the three-months gap between referral and FNAC in this patient could have been avoided with a higher clinical suspicion of malignancy.

A study done in Sarawak prospectively investigated the interlude between onset of symptom, first medical consultation, first ORL clinic consultation, histopathological diagnosis and treatment of head and neck cancer. There was patient delay, and professional delay. Like in this case, late patient presentation due to his lack of awareness might contribute to the delay, similar to other cases' major cause of delay. Furthermore, a common problem is failure of health workers to pick up malignant signs and symptoms [9]. As a rule of thumb, a persistent (chronic) unexplained swelling in the neck is considered malignant until proven otherwise and should be promptly investigated [1, 2].

Complete surgical excision followed by radiotherapy is the treatment of choice for ACC. The aim of neck dissection is to achieve regional control, and when combined with postoperative adjuvant radiotherapy, it ensures a longer disease-free period [10]. In this case, a total parotidectomy was done and the histological report confirmed ACC. This patient was subsequently referred for radiotherapy. He will be on long term follow up with the ORL and oncologist, to monitor for any recurrence or metastasis.

## CONCLUSION

There are genuine challenges in diagnosing ACC due to its clinical characteristics and obscurity in ultrasound findings. Therefore, it is important for primary care physicians to have a high clinical suspicion of malignancy in slow growing salivary gland tumours and not to prematurely conclude it is benign. Suspected tumours ought to be confirmed histologically.

## Conflict of Interest

Authors declare none.

## Acknowledgements

We would like to express our gratitude to all clinicians involved in the care of the patient, specifically, ORL teams and oncology teams. Special appreciation to the patient for consenting to the publication of this case report.

## Authors' contribution

ANI-ZA is the first author, the doctor who saw the patient. FA is the main supervisor for the student and guided the student with the case report. SFBS is the co-supervisor who guided the student with the case report. KMN is the radiologist who did the scans and report on the results findings, and contributed to this case report writing. GCT is the pathologist who reported on the histopathology slides and contributed to this case report writing.

## REFERENCES

1. Haynes J, Arnold K, Aguirre-Oskins C, et al. Evaluation of Neck Masses in Adults. *Am Fam Physician*. 2015;91(10):698-706.
2. National Institute for Health and Care Excellence. Suspected Cancer: Recognition and Referral. NICE guideline. June 2015. [Available from: [www.nice.org.uk/guidance/ng12](http://www.nice.org.uk/guidance/ng12).
3. Galdirs TM, Kappler M, Reich W, et al. Current Aspects of Salivary Gland Tumors – A Systematic Review of the Literature. *GMS Interdiscip Plast Reconstr Surg DGPW* 2019;8(12): 1-8.
4. Boukheris H, Curtis RE, Land CE, et al. Incidence of Carcinoma of the Major Salivary Glands According to the World Health Organization (WHO) Classification, 1992–2006: A Population-Based Study in the United States. *Cancer Epidemiol Biomarkers Prev*. 2009;18(11): 2899–906.
5. Sepúlveda I, Frelinghuysen M, Platina E, et al. Acinic Cell Carcinoma of the Parotid Gland: A Case Report and Review of the Literature. *Case Rep Oncol* 2015;8(1):1–8.
6. Foote FW, Frazell EL. Tumors of the Major Salivary Glands. *Cancer* 1953;6(6):1065-133
7. ICD-11. International Classification of Diseases for Mortality and Morbidity Statistics. 11th revision. World Health Organisation, 2019.
8. Lee YYP, Wong KT, King AD, et al. Imaging of Salivary Gland Tumours. *Eur J Radiol*. 2008; 66:419–36.
9. Lee S, Tang I, Avatar S, Ahmad N, Selva K, Tay K, et al. Head and Neck Cancer: Possible Causes for Delay in Diagnosis and Treatment. *Med J Malaysia*. 2011;66(2):101-4.
10. Hishamuddin NHAN, Azman M, Kong MH, et al. Neck Dissection for Head and Neck Malignancies: A Malaysian 13 Years Review. *Bangladesh j. med. sci.* 2017;16(3):384–96.